

ORIGINAL RESEARCH ARTICLE

Experimental study on the preservation of amputated limb by low-temperature HTK preservation solution arterial perfusion

Shi Zhuang^{1,2}, Bayarmaa Enkhbat^{2,3}, Sergelen Orgoi⁴, Sayamaa Lkhagvadorj^{2,3,*}

¹ Department of Orthopedics, Affiliated Hospital of Inner Mongolia Minzu University, Tongliao 028000, China

² Department of Pathology and Forensic Medicine, School of Biomedicine, Mongolian National University of Medical Sciences, Ulaanbaatar 14021, Mongolia

³ Department of Pathology, Mongolia-Japan Hospital, Mongolian National University of Medical Sciences, Ulaanbaatar 14021, Mongolia

⁴ Department of Surgery, School of Medicine, Mongolian National University of Medical Sciences, Ulaanbaatar 14021, Mongolia

* Corresponding author: Sayamaa Lkhagvadorj, sayamaa@mnums.edu.mn

ABSTRACT

Objective: To evaluate the effect of HTK (Histidine-Tryptophan-Ketoglutarate solution) infusion on the protection and replantation of amputated limb. **Methods:** In experiment 1, the amputated limbs of male New Zealand white rabbits were preserved by different preservation methods, including low-temperature HTK solution perfusion group, low-temperature normal saline perfusion group, low-temperature preservation group and non-perfusion group at normal temperature. The homogenates of muscle tissue at different time points were collected for biochemical detection. H&E (hematoxylin and eosin) staining was performed on muscle tissue. Bax, Bcl-2 protein immunohistochemical staining and TUNEL method were used to detect apoptosis in muscle, nerve, and vascular tissues. The ultrastructure of cells was observed by transmission electron microscope. In experiment 2, the amputated limbs of rabbits were treated with HTK perfusion and cryopreservation without perfusion, respectively. The survival of rabbits and their limbs were observed, and detected by H&E, TUNEL (Terminal deoxynucleotidyl transferase dUTP Nick End Labeling) and scanning electron microscopy. Statistical analysis was performed using SPSS 22 (SPSS Inc., Chicago, IL, USA). χ^2 test, student's t-test, and ANOVA (Analysis of Variance) were used to compare the categorical and continuous variables. **Results:** Experiment 1: With the extension of disconnection time, there were statistical differences between the biochemical indexes of the HTK liquid perfusion group and those of the non-low temperature non-perfusion group, while some indexes of the other groups were different. Immunohistochemical staining of tissues (muscle, nerve, and blood vessel) in each group showed that the number of cells stained by anti-apoptotic protein BCL-2 in each group significantly increased with the extension of time, while the number of cells stained by pro-apoptotic protein BAX2 in each group significantly decreased. TUNEL test showed that compared with other treatment groups, the apoptosis rate of the HTK liquid group was significantly decreased. Experiment 2: The survival rate of the experimental group was 60%, and that of the control group was only 30%. H&E staining, the TUNEL method and scanning electron microscopy suggested that HTK infusion could reduce ischemia-reperfusion injury in muscle tissue. **Conclusion:** 1. Perfusion preservation of severed limbs at 4 °C can effectively reduce tissue damage caused by ischemia and hypoxia, and the effect is stronger than direct preservation. 2. HTK solution and normal saline were used for one-time perfusion of the severed limbs of rabbits, and the preservation effect of HTK solution was the best. 3. HTK solution was used for one-time perfusion of severed hind limbs of rabbits, which was refrigerated at 4 °C and then replanted (ischemia time was 3–5 h). Compared with the replanted limbs after cold storage alone, the survival rate was higher, and the postoperative ischemia and hypoxia injury of surviving limbs were less.

Keywords: amputated limb; organ preservation solution; perfusion; HTK infusion; back planting

ARTICLE INFO

Received: 25 January 2024
Accepted: 7 February 2024
Available online: 28 March 2024

COPYRIGHT

Copyright © 2024 by author(s).
Trends in Immunotherapy is published by
EnPress Publisher, LLC. This work is
licensed under the Creative Commons
Attribution-NonCommercial 4.0 International
License (CC BY-NC 4.0).
<https://creativecommons.org/licenses/by-nc/4.0/>

1. Introduction

In clinical practice, it is not only the technical level of microsurgery that affects the survival rate and postoperative functional recovery of amputated limbs but also the correct and reasonable preservation methods of amputated limbs^[1]. How to preserve the severed limbs reasonably and effectively before surgery, reduce the tissue damage caused by ischemia and hypoxia, delay the metabolic process, provide energy for the severed tissues, remove the accumulation of metabolic and toxic products in the tissues, and prolong the degeneration and necrosis of tissue cells has become particularly critical^[2]. Before the reconstruction of blood circulation, the amputated limb should be reasonably preserved simply and inexpensively to reduce ischemia-reperfusion injury, gain precious time for replantation and improve the survival rate of replantation and postoperative functional recovery^[3]. The composition of the limb is complex and different from that of the visceral organs with a relatively simple composition. Currently, there is no liquid specially used for the preservation and perfusion of the limb in clinics. So, what kind of liquid infusion can be used to achieve better results? Nowadays, the transplantation technology of solid organs such as kidney, liver and heart has been relatively mature.

We have accumulated a lot of experience in perioperative organ preservation and postoperative immune rejection prevention. Before transplantation, UW fluid perfusion of donor kidney^[4] and HTK fluid perfusion of donor heart can achieve good functional protection, which has become an international consensus^[5]. According to the different degrees of tolerance of different tissues to ischemia and hypoxia, effective tissue perfusion can usually preserve the heart for 24 h, the liver for nearly 30 h, and the kidney even for 72 h^[6,7]. The purpose of this experiment is to verify through animal experiments, compare the protection effect of amputated limb preservation methods commonly used at home and abroad on rabbit amputated limb, which is the strongest, find out the protection method suitable for amputated limb perfusion, delay the process of tissue degeneration, prolong the preservation time of amputated limb activity, reduce the tissue damage caused by ischemia and hypoxia. And lay experimental experience and clinical foundation for improving the survival rate of replanted limbs.

2. Materials and methods

2.1. Ethics approval and grouping of experimental animals

This study has been approved by the Institutional Ethics Committee of Ethics Committee of Mongolian National University of Medical Sciences (MNUMS-2019-12-20) and Affiliated hospital of Inner Mongolla University for The Nationalities Approval Notice (NM-LL-2019-06-02-01) and has followed the principles outlined in the Declaration of Helsinki.

In Experiment 1, a comparative study of different preservation methods for the amectomy limbs of experimental animals: 40 healthy adult New Zealand white rabbits (male, 2–2.5 kg) after 1 week of adaptation were randomly divided into 4 groups with 10 rabbits in each group: the blank control, the cryopreservation, the normal saline perfusion, and the HTK infusion, respectively.

Experiment 2, a comparative study on re-transplantation of severed limbs: 20 healthy adult New Zealand white rabbits after 1 week of adaptation were randomly divided into 2 groups, including the blank control and the HTK infusion, with 10 rabbits in each group.

2.2. Preparation of animal models

Model preparation for experiment 1: Slow injection of 1.5% pentobarbital sodium (2 ml/kg) through the auricular vein for anesthesia; After the anesthesia was stable, the lower limbs, abdomen, and back were shaved and fixed in the supine position on the animal operating table. The surgical area was disinfected with iodophors, and a sterile surgical sheet was laid. The skin and subcutaneous tissue were cut through the curved incision line in the bilateral groin, and the femoral artery, vein, and sciatic nerve were separated under the surgical microscope. Cut off femoral arteries and veins and flush the lumen with an anticoagulant flushing solution. The femoral artery and femoral vein were punctured with an indwelling trocar and fixed with wire. The severed sciatic nerve, muscle, and other tissues were removed successively, and the femur was severed at 1/3 of the femoral close to the inguinal ligament with a chainsaw. After complete hemostasis by bipolar electrocoagulation, the skin of the broken end was sutured discontinuously with a 5-0 silk thread to wrap the wound to reduce tissue exposure. The severed limbs of the perfusion group were kept in the refrigerator at 4 °C for low-temperature preservation, and the femoral artery holding needle was connected to a volume-based infusion pump. The perfusion fluid was injected from the femoral artery, and the perfusion pressure was 100 cm H₂O for the severed hind limb. The corresponding perfusion fluid was injected according to the groups, and the perfusion was recorded as 0 h until the outflow was clarified (**Figure 1A–D**).

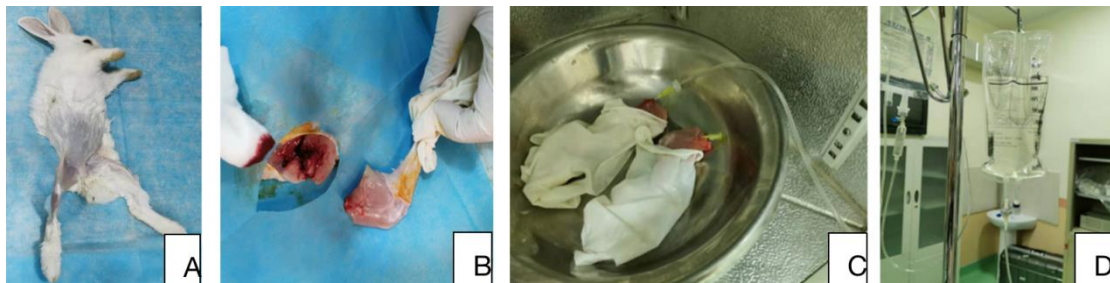


Figure 1. Perfusion diagram of rabbit hind limb dissection. (A) Anesthesia and disinfection; (B) Off the hind limb; (C) The amputated hind limb was infused with HTK solution; (D) The HTK solution is perfused.

Model preparation for experiment 2: Under the same anesthesia method, one side of the lower limb, abdomen, and back were shaved and fixed on the animal operating table in a supine position when the anesthesia was stable. The skin was cut along the groin, the subcutaneous tissue was separated from the groin, and the femoral artery and femoral vein from the inguinal ligament to the medial part of the knee joint were carefully separated under the microscope (10×), and the branch vessels were ligated. The lower limbs were squeezed with elastic bandages for blood displacement, and the femoral arteries and veins were clipped and cut off. After intermittent rinsing with an anticoagulant flushing solution, the outer membrane of the vessels was trimmed, and an indwelling trocar was placed for puncture and fixed by binding. A chainsaw was used to cut off 1/3 of the femur, and then the muscles and nerves of the hind limb were completely cut off. After complete hemostatic treatment with bipolar electric coagulation, the severed femur was shortened by 3–5 mm, the bone fragments were cleaned, and the bone marrow cavity on both sides of the broken end was rinsed with normal saline. Subcutaneous tissue and skin were sutured with a 5-0 silk thread to close the wound stump and reduce tissue exposure, and then wrapped with wet gauze of normal saline and stored as required. The severed

limbs in the perfusion group were kept in a 4 °C refrigerator at a low temperature, and the severed hind limbs were perfused with the corresponding solution from the remaining inset trocar at the perfusion pressure of 100 cm H₂O until the femoral vein and wound outflow were clarified and the toes were white. The drip rate was not controlled, the needle was pulled out after perfusion, and the wounds of severed limbs were wrapped with saline gauze in both the experimental group and the control group. The limbs covered with gauze were placed in a clean petri dish with a lid and refrigerated at 4 °C. The experimental animals were given 200 mL of supplemental hydroxyethyl starch injection during and after the operation and placed in a single cage until recovery from anesthesia (**Figure 2A–C**).

2.3. Back implantation of the amputated limb model of experimental animals

Anesthesia was fixed again with the same method; iodophor was used to disinfect the surgical area; sterile surgical sheets were laid; suture lines were removed; iodophor was disinfected; and Kirschner wire of appropriate thickness and length was inserted into the bone marrow cavity on both sides of the broken end of the femur to fix the femoral shaft. Under the surgical microscope (10×), the femoral arteriovenous and femoral nerves were anastomosed end to end with the 10-0 microsuture line. The arteriovenous and venous stitches were 8–10 each, and the arteriovenous arteries and veins were unobtrusive without obvious bleeding. Then the wound was rinsed, and hemostasis was stopped. After the wound was disinfected with alcohol again, an intravenous drip of dextran 40 injections (100 mL) to supplement blood volume, 1 mL of heparin saline for anticoagulation, inject papaverine solution (1.5 mg) into the muscle and put it back into the cage (**Figure 2D–F**). After operation, all experimental animals were kept in a single cage, kept dry and clean, and paid attention to indoor heat preservation (27–28 °C). Pay attention to the bleeding of the wound; if there is more blood near the wound, an alcohol gauze ball should be wiped away.

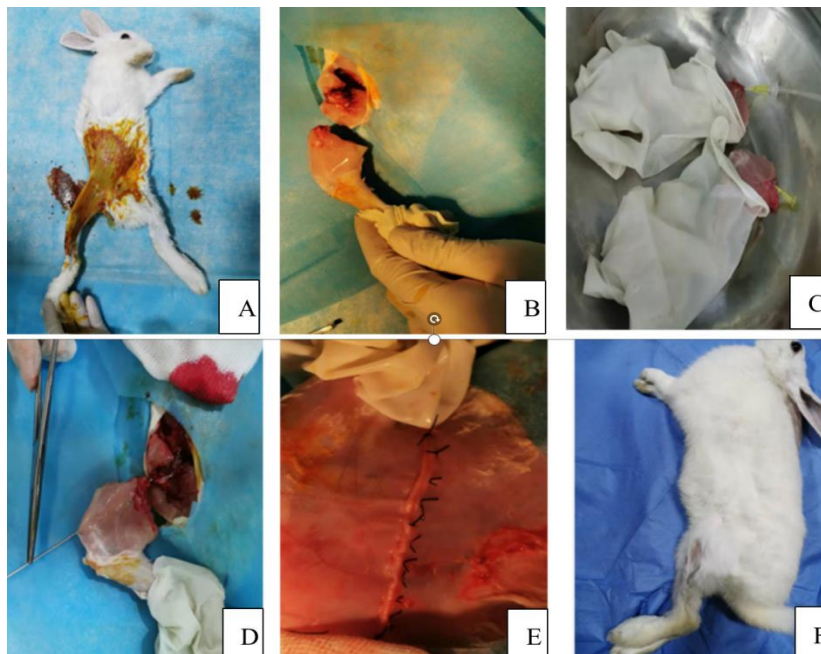


Figure 2. Replantation of experimental rabbit. (A) Anesthesia and disinfection; (B) Off the hind limb; (C) The amputated hind limb was infused with HTK solution; (D) Hind limb replantation; (E) Suture of hind limb; (F) After the recovery of hind limb re-attachment.

2.4. Test items

2.4.1. Biochemical parameters' detection of different preservation methods for the severed limbs of experimental animals

Fresh tibialis anterior muscle, femoral artery, and sciatic nerve were clipped at 6, 12, 18, and 24 h after limb amputation, prepared by tissue homogenization mechanism, centrifuged at 3000 r/min for 10 min with

low temperature and low-speed centrifuge, and the supernatant abandoned precipitate samples were placed in the Hitachi 7170 automatic biochemical analyzer (Zhejiang Xinke Medical Technology Co., Ltd, China) for biochemical following parameters: alkaline phosphatase (ALP), Alanine aminotransferase (ALT), Aspartate aminotransferase (AST), Creatine kinase (CK), Lactate dehydrogenase (LDH), Superoxide dismutase (SOD), Glucose (GLU), and Lactic acid (LAC).

2.4.2. Hematoxylin and Eosin (H&E) staining

The complete tissues of the gastrocnemius muscle, femoral artery, and sciatic nerve were cut at the 6th, 12th, 18th, and 24th hours after the hind limbs of the experimental animals were severed, which were fixed in buffer formalin, embedded, sliced, and stained with H&E staining. Each section was randomly selected with 5 fields under a 400× light microscope and photographed with the same brightness.

2.4.3. Immunohistochemical (IHC) staining

The sections were deparaffinized in xylene, rehydrated in graded alcohols, and washed with reaction buffer followed by incubation with primary BAX antibody (Abcam, Cambridge, MA, USA) and BCL-2 antibody (Abcam, Cambridge, MA, USA) at a 1:50 dilution for 60 min at 42°C. Then followed with biotin secondary antibody (ZhongShan JinQiao, BJ, CN), HRP working solution (Thermofisher, USA), DAB chromogenic solution (Solarbio, CN), and counterstained with hematoxylin (Roche Diagnostics, CH) according to the manufacturer's instructions. Positive and negative control stains were also performed. Photos were taken, and each tissue was randomly selected for statistical analysis. Integral optical density (IOD) and Mean density were analyzed by ImagePro Plus. IOD is the value obtained by adding up all the optical density values of each brown dot on the image. The average optical density (AOD) is the value obtained by dividing IOD by the area of the effective target distribution area.

2.4.4. TUNEL assay for cell apoptosis

The slides were digested with Tris-buffered saline (TBS) (1:200) freshly diluted Proteinase K at 37 °C, followed by labelled buffer and block solution, the biotinized anti-digoxin antibody, and the SABC (streptavidin-biotin complex), then 50μL/tablet was mixed successively and added to the specimen, and 1 mL distilled water was taken. Add a drop of reagents A, B, and C (WL029a, Wanleibio, CN) to the DAB kit (DA1010, Solarbio, CN) mix well, and add them to the specimen piece for colour rendering, dehydration, transparency, and sealing.

2.4.5. Transmission electron microscopy (TEM) study

TEM was used to detect the ultra-histological structure at 12 and 24 hours after dissection. The tissue of the gastrocnemius muscle, femoral artery, and sciatic nerve was fixed in a glutaraldehyde solution, washed with PBS buffer, and then the tissue blocks were immersed in acetone and dehydrated once. The fully dehydrated tissue blocks were immersed in the solution successively: a mixture of dehydrating agent and embedding agent 1 (pure acetone: resin embedding agent = 1:1) at room temperature for 1 h; the mixture of dehydrating agent and embedding agent 2 (pure acetone: resin embedding agent = 1:2) at room temperature for 2 h; pure resin embedding agent, room temperature, overnight. At last, saturated uranium acetate and lead citrate staining were used to prepare ultrathin sections, and the ultrastructure was observed and photos taken under a TEM.

2.4.6. Observation indexes of experimental animals after replantation of severed hind limbs

(1) Pay attention to observing whether the animals died and the survival of the hind limbs after implantation (the colour of the paw). If the animal survived, they were anesthetized again on the 1st or 7th day after surgery, and the wound about 0.5 cm long was cut on the skin of the implanted limb with ophthalmic scissors, and the bleeding of the wound was observed.

(2) The anterior tibial muscle and sciatic nerve tissues were examined by H&E staining, and the muscle

tissues were examined by TUNEL staining and transmission electron microscopy.

(3) One surviving animal in each group was selected for vascular ultrasound measurement at 4 weeks after surgery.

2.5. Statistical analysis

SPSS22 software (SPSS Inc., Chicago, IL, USA) was used for analysis, and the data were expressed as $\bar{x} \pm s$. The homogeneity test of variance was conducted on the experimental data. For homogeneity of variance, repeated measure ANOVA was used for the comparison of biochemical indicators between groups, and a t-test was used for the comparison between groups. The proportion of pathological area in routine H&E staining and immunohistochemical IOD value were compared by factorial design analysis of variance. A T-test was used for ischemic time between the two groups. The rank sum test was used when the variance was not homogeneous. Test standard $\alpha = 0.05$, $p < 0.05$ was considered statistically significant.

3. Results

3.1. Experiment 1

3.1.1. Morphological observation

In the control group, the limbs were severely wrinkled, the feet were greyish-purple in colour, and the toes were slim and close together. In the low-temperature group, the limbs were slightly wrinkled, the foot colour was slightly greyish purple, and the toes were slim and close together. After 24 h refrigeration at 4 °C, the limbs of each perfusion group showed different degrees of swelling, the feet were pink-white to white, and the toes were open. The saline group had the most swelling. The swelling of the HTK group was slighter than that of the normal saline group, and there was no obvious difference between the two groups.

3.1.2. Biochemical parameters

The biochemical results are shown in **Table 1**. Generally, it shows ALP, ALT, AST, CK, LDH and LAC increased gradually, while GLU and SOD decreased gradually with the extension of discontinuation time.

Table 1. Biochemical results of amputated hind limbs in rabbits ($\bar{X} \pm S$, $n = 10$).

Biochemical indexes	Time (h)	Normal saline group	Cryopreservation group	HTK liquid group	Control group
ALT (IU/L)	0	25.30 ± 4.28	26.87 ± 5.92	23.45 ± 3.44	24.83 ± 4.97
	6	36.82 ± 3.98	36.30 ± 5.19	32.00 ± 2.29 ^{##}	43.52 ± 1.18
	12	40.98 ± 7.54	42.98 ± 3.16	38.00 ± 5.64 ^{**}	51.00 ± 4.57
	18	56.00 ± 8.03	48.13 ± 2.02	44.43 ± 1.68	59.43 ± 1.98
	24	62.25 ± 1.30	52.82 ± 7.31	50.53 ± 4.19	73.22 ± 2.20
ALP (IU/L)	0	29.1 ± 1.22	27.57 ± 1.15	28.15 ± 2.80	29.68 ± 1.99
	6	63.5 ± 3.58	62.85 ± 3.66	52.45 ± 1.85	72.98 ± 2.60
	12	88.1 ± 2.53	92.88 ± 2.10	82.46 ± 2.88 ^{**Δ}	103.41 ± 5.47
	18	105.6 ± 4.60	112.98 ± 4.60	92.67 ± 1.55 ^{**Δ}	123.53 ± 3.66
	24	162.2 ± 2.33	173.37 ± 2.85	122.68 ± 1.60	193.55 ± 4.86
AST (U/L)	0	38.68 ± 4.74	40.48 ± 3.99	38.57 ± 2.50	43.23 ± 2.32
	6	68.58 ± 3.55	66.78 ± 3.61	58.70 ± 1.30 ^Δ	79.82 ± 4.35
	12	102.58 ± 1.70	117.10 ± 8.95	98.85 ± 4.80 ^{**Δ}	126.08 ± 4.49
	18	110.93 ± 3.45	139.68 ± 4.80	104.48 ± 5.37 ^{**Δ}	192.23 ± 1.46
	24	200.12 ± 6.61	212.20 ± 6.27	142.87 ± 6.09	234.37 ± 5.61
CK (U/L)	0	1678.17 ± 49.84	1496.83 ± 39.12	1486.50 ± 91.05	1819.17 ± 143.29
	6	2282.17 ± 38.39	2184.50 ± 37.26 ^Δ	1548.33 ± 90.96 ^Δ	2597.17 ± 538.85
	12	2700.33 ± 61.96	2675.17 ± 67.21	1958.83 ± 42.87 ^Δ	3186.50 ± 816.92

Table 1. (Continued).

Biochemical indexes	Time (h)	Normal saline group	Cryopreservation group	HTK liquid group	Control group
LDH (U/L)	18	2958.83 ± 45.77	3134.83 ± 41.96	2209.00 ± 38.88	3710.33 ± 340.35
	24	3390.83 ± 42.04	3833.50 ± 31.87	2719.67 ± 41.52	4286.50 ± 547.56
	0	104.50 ± 42.82	123.17 ± 78.89	123.91 ± 39.09	128.33 ± 45.56
	6	251.33 ± 31.73	255.67 ± 94.25 ^{ΔΔ}	247.50 ± 25.96 ^{**ΔΔ}	318.83 ± 50.18
	12	309.00 ± 47.37	329.17 ± 96.74	298.50 ± 65.65 ^{**ΔΔ}	371.83 ± 49.74
	18	391.50 ± 61.16	408.83 ± 50.79	321.90 ± 99.76	433.83 ± 44.09
GLU (mmol/L)	24	439.50 ± 53.20	482.50 ± 37.18	357.83 ± 28.78	579.83 ± 78.34
	0	6.097 ± 1.06	5.333 ± 0.96	5.365 ± 1.11	5.342 ± 1.08
	6	5.275 ± 2.07	4.310 ± 1.08	4.298 ± 0.13	4.272 ± 0.36
	12	4.250 ± 0.92	4.248 ± 1.03	4.278 ± 0.06 ^{ΔΔ}	3.213 ± 0.75
	18	3.245 ± 1.04	3.240 ± 0.84	4.322 ± 0.19	2.197 ± 0.93
	24	2.245 ± 0.840	2.240 ± 0.94	3.852 ± 0.19	1.187 ± 1.04
LAC (mmol/L)	0	0.717 ± 0.073	0.848 ± 0.100	0.993 ± 0.27	0.79 ± 0.08
	6	1.533 ± 0.098 ^{ΔΔ}	1.860 ± 0.347 ^{**ΔΔ}	1.467 ± 0.30 ^{ΔΔ}	1.97 ± 0.24
	12	1.782 ± 0.080	1.928 ± 0.247 ^{^^}	1.720 ± 0.29	2.33 ± 0.29
	18	2.300 ± 0.100	2.405 ± 0.264	1.872 ± 0.40	2.82 ± 0.45
	24	2.790 ± 0.160	2.892 ± 0.196	2.393 ± 0.36	3.332 ± 0.58
	0	96.38 ± 5.89	94.60 ± 8.92	92.08 ± 8.36	91.87 ± 5.38
SOD (U/mL)	6	81.02 ± 11.46	81.72 ± 3.85 ^{^^}	77.90 ± 8.82 ^{**ΔΔ}	82.50 ± 9.68
	12	78.37 ± 10.96	75.70 ± 8.49	72.38 ± 9.04 ^{**ΔΔ}	78.47 ± 1.01
	18	67.50 ± 7.64	69.55 ± 1.58	64.50 ± 4.10	69.78 ± 4.10
	24	58.82 ± 9.46	58.62 ± 4.97	53.71 ± 10.60	56.03 ± 8.55

** $P < 0.05$ vs normal saline group, ^{ΔΔ} $P < 0.05$ vs control group, ^{##} $P < 0.05$ cryopreservation group, ^{^^} $P < 0.05$ vs HTK liquid group.

ALP: With the extension of disconnection time, ALP of each group showed a gradually increasing trend, and there were statistical differences between HTK liquid group and normal saline group, HTK liquid group and control group, respectively ($p < 0.05$);

ALT: With the extension of disconnection time, the ALT level of each group showed a gradual increasing trend, and there were statistical differences between HTK liquid group and normal saline group, HTK liquid group and low-temperature group ($p < 0.05$);

AST: With the extension of disconnection time, the AST level of each group showed a gradually increasing trend, and there were statistical differences between HTK liquid group and normal saline group and HTK liquid group and control group ($p < 0.05$);

CK: With the extension of disconnection time, the CK level of each group showed a gradual increasing trend, among which, there were statistical differences between the low-temperature group and the HTK liquid group compared with the control group ($p < 0.05$);

LDH: With the extension of disconnection time, the LDH level of each group showed a gradual increasing trend, and there were statistical differences between HTK liquid group and normal saline group, HTK liquid group and control group, and low-temperature group and control group ($p < 0.05$);

LAC: With the extension of disconnection time, LAC level of each group showed a gradual increasing trend, among which, there were statistical differences between the low-temperature group and the normal saline group, the HTK liquid group and the low-temperature group, the low-temperature group and the control

group, the normal saline group and the HTK liquid group and the control group ($p < 0.05$);

GLU: With the extension of disconnection time, the level of GLU in each group showed a gradually decreasing trend, and there was a statistical difference between HTK liquid group and control group ($p < 0.05$);

SOD: With the extension of disconnection time, the SOD level of each group showed a gradually decreasing trend, and there were statistical differences between HTK liquid group and normal saline group, HTK liquid group and low-temperature group, HTK liquid group and control group ($p < 0.05$); No statistical difference was found among the other indicators in each group ($p > 0.05$).

3.1.3. Histological results

Histological analysis of H&E cell area showed that with the extension of dissociation time, the proportion of cell area in the four groups showed a gradually decreasing trend, and the proportion of cell area in the normal saline group was closest to the normal value (0h) at 6 h. During 6–18 h, although the cell edema (larger area of individual cells and lighter staining of cells), the inter-stromal edema (the area in the visual field other than cells) was more pronounced, resulting in a rapid decline in the proportion of cell area. The cell area of the other three groups at 6 h was lower than that of the normal saline group, but the decrease trend was relatively gentle after 6 h. The proportion of cell area in the non-perfusion group was the lowest at all-time points, while the proportion of cell area in the normal saline group was the highest at 6 h and 12 h, and the proportion of cell area in the HTK solution at 18 h and 24 h was the lowest among the four groups. The differences among all groups were statistically significant ($p < 0.05$). There were significant differences between the Cryopreservation group, HTK group and normal saline group ($p < 0.05$); At 12 h, there were statistical differences between the normal saline group, HTK group and non-perfusion group, and there were statistical differences between the Cryopreservation group and normal saline group ($p < 0.05$). At 18 h and 24 h, there were statistical differences between the HTK-only group and the non-perfusion group ($p < 0.05$), see **Figure 3**.

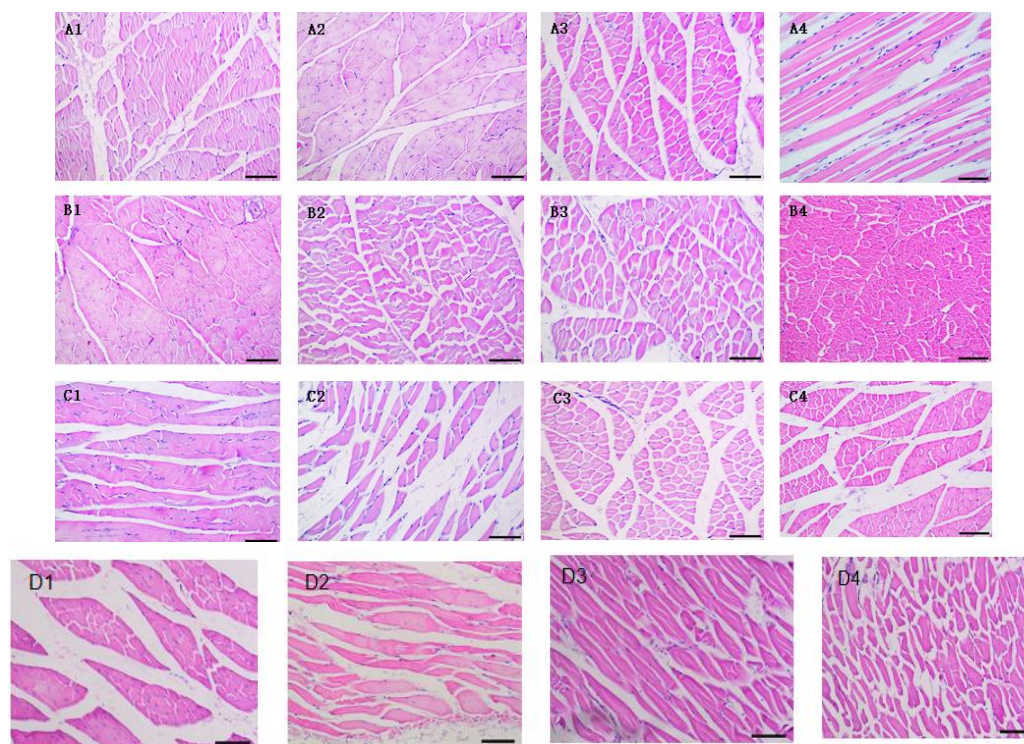


Figure 3. Histopathological findings of the after-severed hind limbs of rabbits in each group (100 \times). Normal saline group for 6 hours (A1), 12 hours (A2), 18 hours (A3), and 24 hours (A4). Cryopreservation group for 6 hours (B1), 12 hours (B2), 18 hours (B3), and 24 hours (B4). HTK liquid group for 6 hours (C1), 12 hours (C2), 18 hours (C3), and 24 hours (C4). Control group for 6 hours (D1), 12 hours (D2), 18 hours (D3), and 24 hours (D4).

3.1.4. Immunohistochemical results

Tissues of each group (muscle, nerve, and blood vessel) were stained by immunohistochemistry, and the results were shown in **Figures 4–9**; Compared with the control group, the number of cells stained by anti-apoptotic protein BCL-2 was significantly increased and the number of cells stained by pro-apoptotic protein BAX2 was significantly decreased with the extension of time in HTK liquid group. Compared with the control group, although the number of cells stained by the anti-apoptotic protein BCL-2 increased in the normal saline group and the number of cells stained by the pro-apoptotic protein BAX2 decreased in the tissue cells of each group, there was no statistical difference, only an increasing or decreasing trend (**Figure 4**).

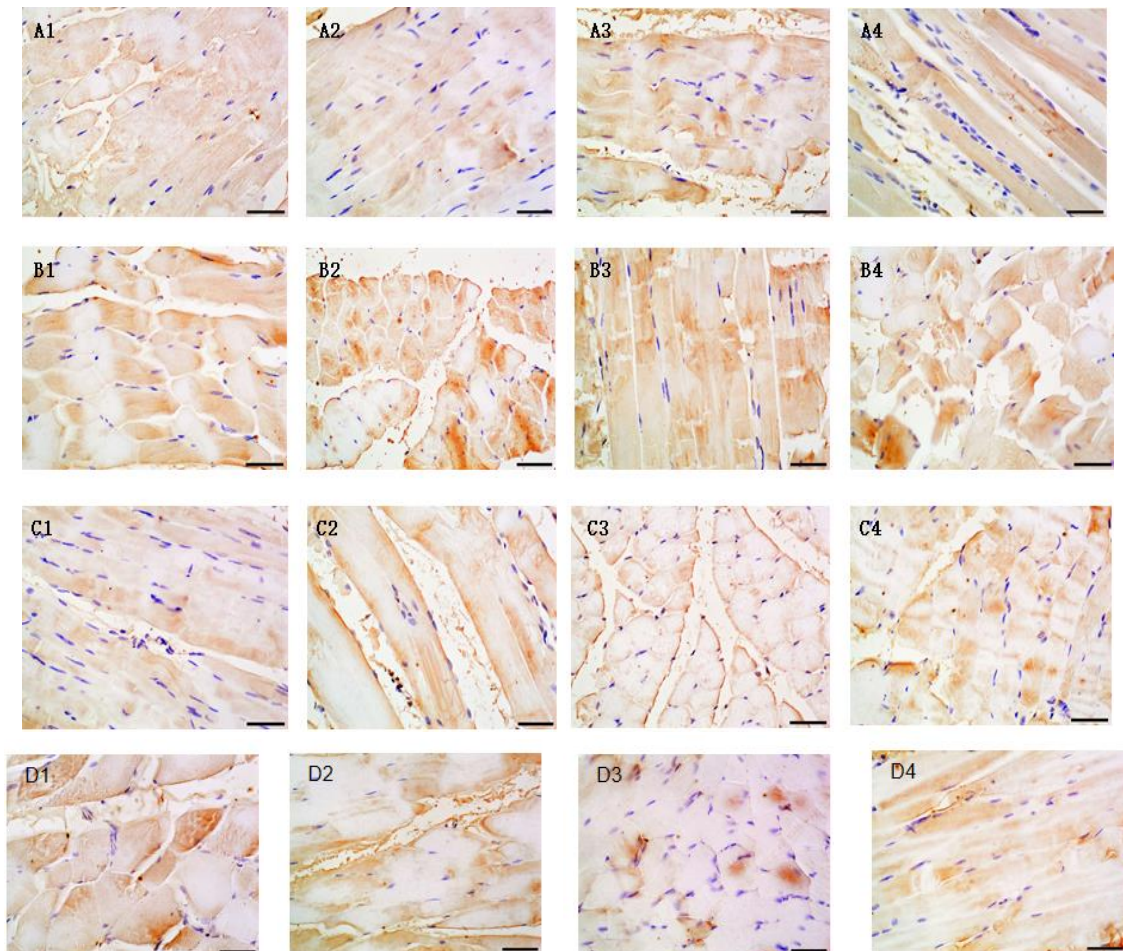


Figure 4. Immunohistochemical staining for Bax in muscle tissue of after-severed hind limbs of rabbits (400 \times). Normal saline group for 6 hours (A1), 12 hours (A2), 18 hours (A3), and 24 hours (A4). Cryopreservation group for 6 hours (B1), 12 hours (B2), 18 hours (B3), and 24 hours (B4). HTK liquid group for 6 hours (C1), 12 hours (C2), 18 hours (C3), and 24 hours (C4). Control group for 6 hours (D1), 12 hours (D2), 18 hours (D3), and 24 hours (D4).

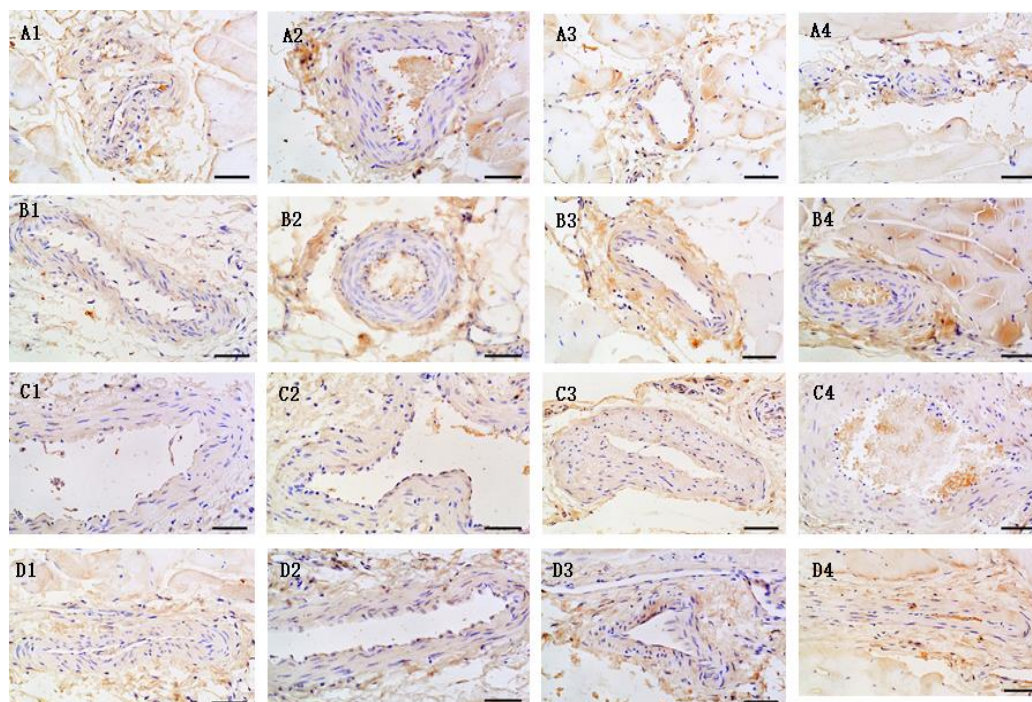


Figure 5. Results of IHC for detecting Bax protein in blood vessels of severed hind limbs of rabbits (400×): (A1) normal saline group for 6h; (A2) normal saline group for 12h; (A3) Normal saline group 18h; (A4) normal saline group 24h; (B1) Cryopreservation group for 6h; (B2) Cryopreservation group for 12h; (B3) Cryopreservation group for 18h; (B4) Cryopreservation group for 24h; (C1) HTK liquid group 6h; (C2) HTK liquid group for 12h; (C3) HTK liquid group 18h; (C4) HTK liquid group 24h; (D1) control group for 6h; (D2) control group for 12h; (D3) control group for 18h; (D4) control group for 24h.

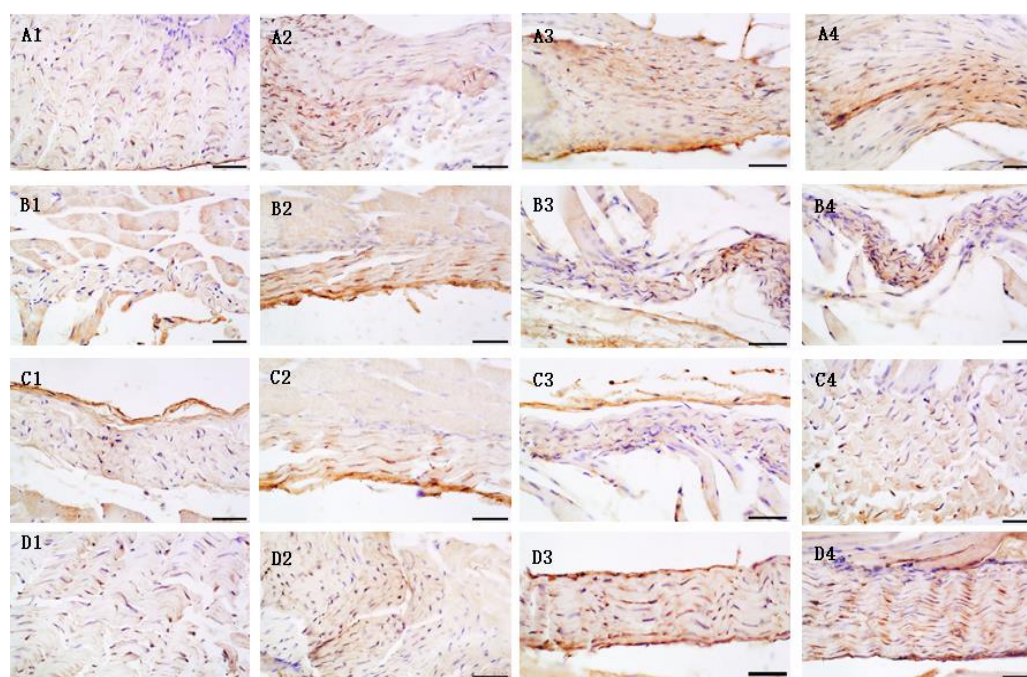


Figure 6. Results of IHC for detecting Bax protein in nerves of severed hind limbs of rabbits (400×). (A1) normal saline group for 6h; (A2) normal saline group for 12h; (A3) Normal saline group 18h; (A4) normal saline group 24h; (B1) Cryopreservation group for 6h; (B2) Cryopreservation group for 12h; (B3) Cryopreservation group for 18h; (B4) Cryopreservation group for 24h; (C1) HTK liquid group 6h; (C2) HTK liquid group for 12h; (C3) HTK liquid group 18h; (C4) HTK liquid group 24h; (D1) control group for 6h; (D2) control group for 12h; (D3) control group for 18h; (D4) control group for 24h.

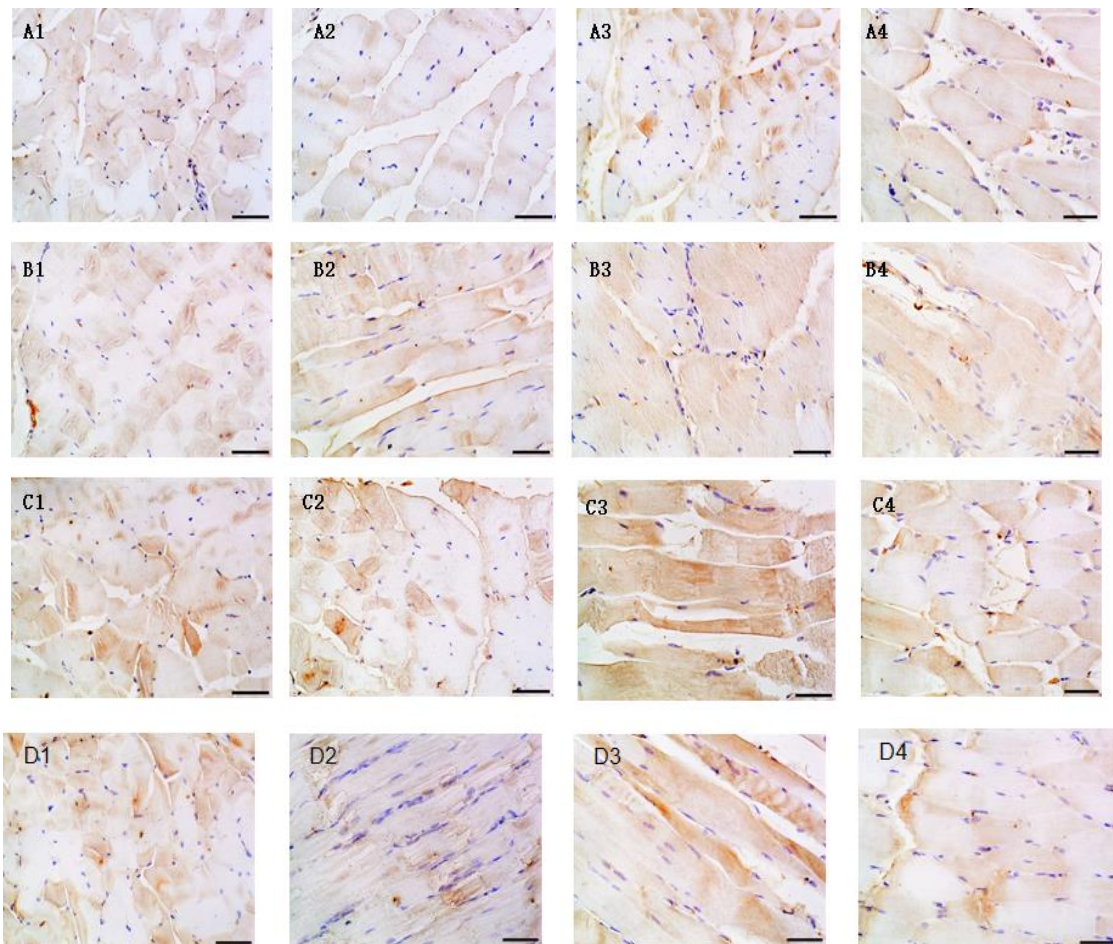


Figure 7. Results of IHC for detecting BCL-2 protein in muscle tissue of severed hind limbs of rabbits (400×); (A1) normal saline group for 6h; (A2) normal saline group for 12h; (A3) Normal saline group 18h; (A4) normal saline group 24h; (B1) Cryopreservation group for 6h; (B2) Cryopreservation group for 12h; (B3) Cryopreservation group for 18h; (B4) Cryopreservation group for 24h; (C1) HTK liquid group 6h; (C2) HTK liquid group for 12h; (C3) HTK liquid group 18h; (C4) HTK liquid group 24h; (D1) control group for 6h; (D2) control group for 12h; (D3) control group for 18h; (D4) control group for 24h.

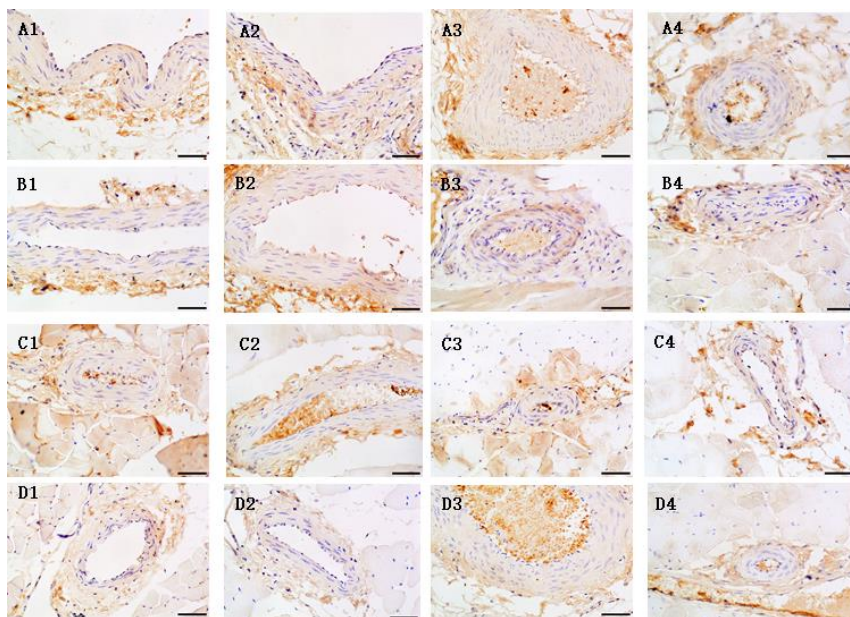


Figure 8. Results of IHC for detecting BCL-2 protein in blood vessels of severed hind limbs of rabbits (400×); (A1) normal saline group for 6h; (A2) normal saline group for 12h; (A3) Normal saline group 18h; (A4) normal saline group 24h; (B1) Cryopreservation group for 6h; (B2) Cryopreservation group for 12h; (B3) Cryopreservation group for 18h; (B4) Cryopreservation group for 24h; (C1) HTK liquid group 6h; (C2) HTK liquid group for 12h; (C3) HTK liquid group 18h; (C4) HTK liquid group 24h; (D1) control group for 6h; (D2) control group for 12h; (D3) control group for 18h; (D4) control group for 24h.

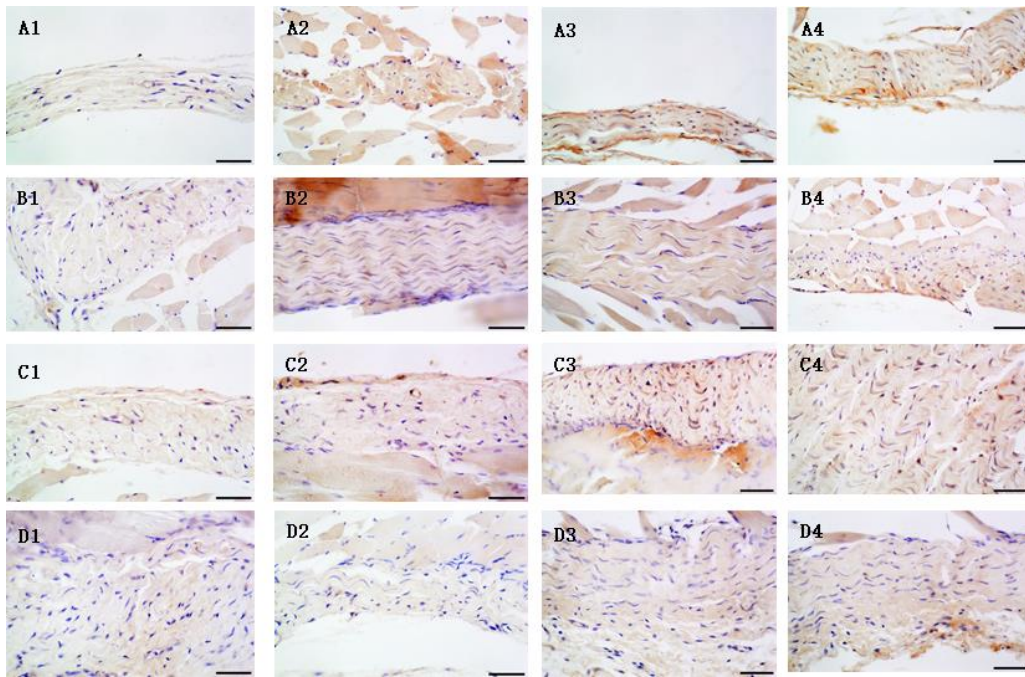


Figure 9. Results of IHC for detecting BCL-2 protein in nerves of severed hind limbs of rabbits (400×); (A1) normal saline group for 6h; (A2) normal saline group for 12h; (A3) Normal saline group 18h; (A4) normal saline group 24h; (B1) Cryopreservation group for 6h; (B2) Cryopreservation group for 12h; (B3) Cryopreservation group for 18h; (B4) Cryopreservation group for 24h; (C1) HTK liquid group 6h; (C2) HTK liquid group for 12h; (C3) HTK liquid group 18h; (C4) HTK liquid group 24h; (D1) control group for 6h; (D2) control group for 12h; (D3) control group for 18h; (D4) control group for 24h.

3.1.5. TUNEL results

The apoptosis rate of the control group increased with the extension of time. In the HTK group, although the amount of apoptosis in blood vessels decreased with the extension of time, the amount of apoptosis in nerve and muscle tissue increased with the extension of time, but compared with other treatment groups, the rate of apoptosis significantly decreased. There was no significant difference in the number of apoptotic cells in blood vessels in the normal saline group and the cryopreservation group compared with the control group, but the number of apoptotic cells in nerve and muscle tissue was also significantly decreased (**Figures 10–12**).

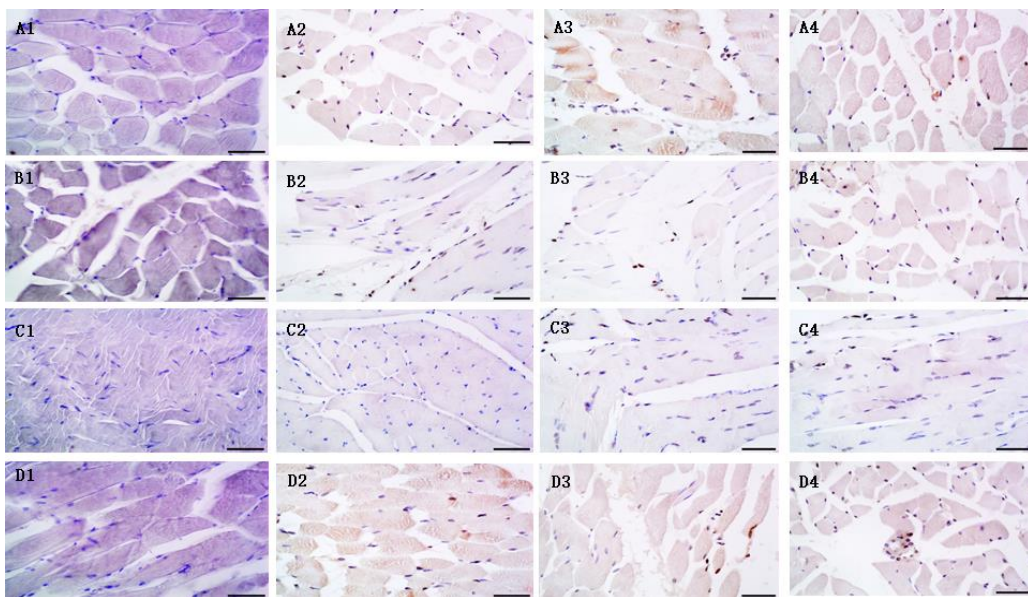


Figure 10. Apoptosis of muscle tissue endothelial cells in severed hind limbs of rabbits detected by Tunnell method (400×); (A1) normal saline group for 6h; (A2) normal saline group for 12h; (A3) Normal saline group 18h; (A4) normal saline group 24h; (B1) Cryopreservation group for 6h; (B2) Cryopreservation group for 12h; (B3) Cryopreservation group for 18h; (B4) Cryopreservation group for 24h; (C1) HTK liquid group 6h; (C2) HTK liquid group for 12h; (C3) HTK liquid group 18h; (C4) HTK liquid group 24h; (D1) Control group for 6h; (D2) Control group for 12h; (D3) Control group for 18h; (D4) Control group for 24h.

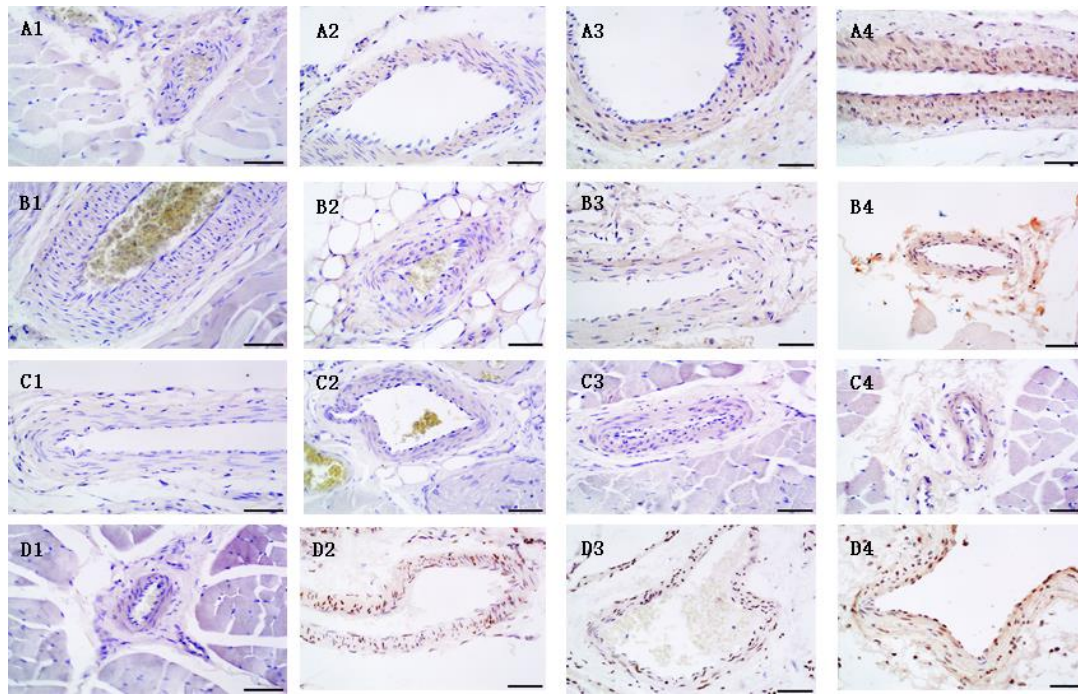


Figure 11. Apoptosis of vascular endothelial cells in severed hind limbs of rabbits detected by TUNEL method (400×); (A1) normal saline group for 6h; (A2) normal saline group for 12h; (A3) Normal saline group 18h; (A4) normal saline group 24h; (B1) Cryopreservation group for 6h; (B2) Cryopreservation group for 12h; (B3) Cryopreservation group for 18h; (B4) Cryopreservation group for 24h; (C1) HTK liquid group 6h; (C2) HTK liquid group for 12h; (C3) HTK liquid group 18h; (C4) HTK liquid group 24h; (D1) Control group for 6h; (D2) Control group for 12h; (D3) Control group for 18h; (D4) Control group for 24h.

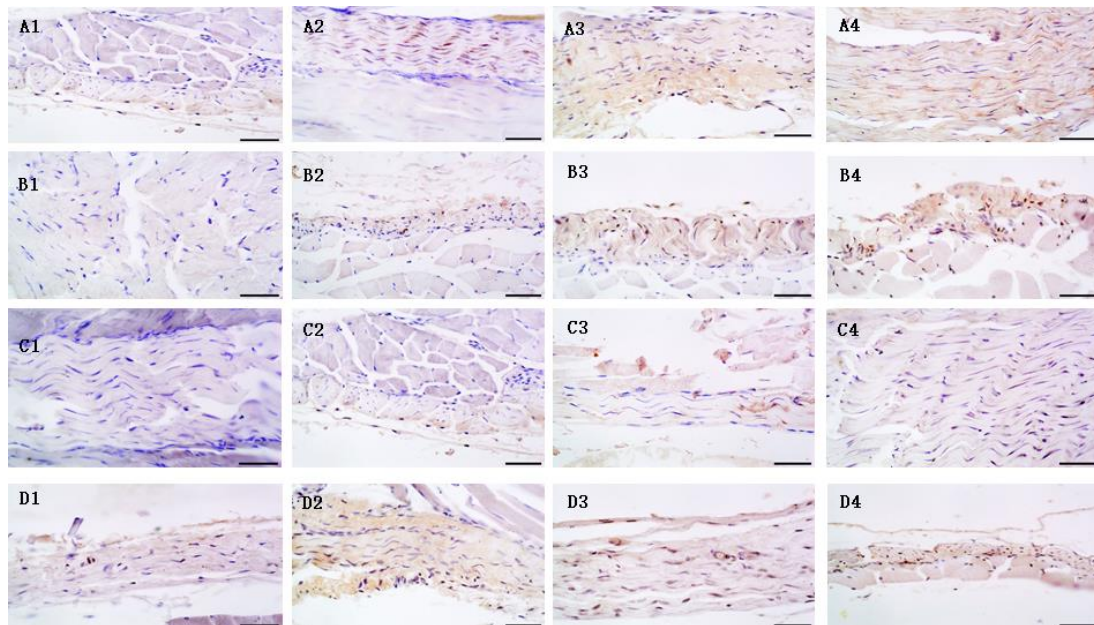


Figure 12. Apoptosis of nerves endothelial cells in severed hind limbs of rabbits detected by TUNEL method (400×); (A1) normal saline group for 6h; (A2) normal saline group for 12h; (A3) Normal saline group 18h; (A4) normal saline group 24h; (B1) Cryopreservation group for 6h; (B2) Cryopreservation group for 12h; (B3) Cryopreservation group for 18h; (B4) Cryopreservation group for 24h; (C1) HTK liquid group 6h; (C2) HTK liquid group for 12h; (C3) HTK liquid group 18h; (C4) HTK liquid group 24h; (D1) Control group for 6h; (D2) Control group for 12h; (D3) Control group for 18h; (D4) Control group for 24h.

3.1.6. Transmission electron microscope ultrastructure

The ultrastructure of each group was detected by transmission electron microscopy (see **Figure 13**), and the statistical results are shown in **Table 2**.




Figure 13. Ultrastructure of amputated hind limbs of each group detected by scanning electron microscopy (10000×); (A1) Normal saline group for 12 h; (A2) Normal saline 24 h; (B1) Cryopreservation group for 12 h; (B2) Cryopreservation group for 24 h; (C1) HTK liquid group for 12 h; (C2) HTK liquid group 24 h; (D1) Control group for 12 h; (D2) Control group for 24 h.

Table 2. Ultra-histological and transmission electron microscopy results of amputated hind limbs of rabbits.

Time	Normal saline group	Cryopreservation group	HTK liquid group	Control group
0 h	The skeletal muscle structure is clear, the fibers are arranged neatly, the muscle segment and each line, the band structure is clear. Mitochondrial number cristae and mitochondrial membrane are complete and have clear structure. Nuclear and chromatin structure is normal.			
12 h	The skeletal muscle structure is basically clear, the fibers are arranged neatly, the muscle space is widened, the sarcomere structure is basically clear, and some regional lines and bands are not orderly. The number of mitochondria is basically normal, relatively swollen, part of it is vacuolar. Nuclear dye Color quality edge shift. The number of glycogen particles decreased.	The skeletal muscle structure is basically clear, the fibers are arranged neatly, the muscle space is widened, the sarcomere structure is basically clear, some sarcomere is destroyed, and the lines and bands are basically clear. The number of mitochondria was normal, the mitochondrial cristae was neatly arranged, and some vacuoles were denaturated. Chromatin edge shift. The number of glycogen particles decreased.	The skeletal muscle structure is basically clear, the fibers are arranged neatly, the muscle segment structure is basically clear, and the band and line structure of individual areas are slightly fuzzy. The number and morphology of mitochondria were not significantly changed, and mitochondrial cristae were neatly arranged. Swelling. Chromatin edge shift. The number of glycogen particles decreased	The skeletal muscle structure is clear, the fibers are arranged neatly, the muscle space is widened, the muscle segment structure is basically clear, and the line and band structure of some areas are slightly fuzzy. The number of mitochondria was slightly more normal than other groups, the volume was swollen, and some of them were vacuolar. Chromatin edge shift. The number of glycogen particles decreased.
24 h	In skeletal muscle, some muscle segments are damaged and flaky, and the structure of some myofibrillar fibers is disappeared or lumpy, with irregular lines and bands. Most of the mitochondrial cristae disappeared and cavitation degeneration occurred. Chromatin edge shift. The glycogen particles almost disappeared.	In skeletal muscle, some fibers are shortened, some sarcomere is destroyed, a small number of myofibrillar structures disappear or clumps condense, and all lines and bands are indistinguishable. Most of the mitochondrial cristae disappeared and cavitation degeneration occurred. Chromatin edge shift. The number of glycogen particles decreased significantly.	The changes were basically the same as those in the cryopreservation group	Skeletal muscle almost all the destruction of sarcomere, fragmented, can not identify the lines, bands; The volume of mitochondria was enlarged and vacuolar. The nuclear chromatin is agglomerated. The glycogen particles almost disappeared.

3.2. Experiment 2

3.2.1. Experimental results after replanting of severed hind limbs of experimental animals

Ischemic time and replantation of severed hind limbs in rabbits: The ischemic time of severed hind limbs of rabbits in the HTK liquid perfusion group and the control group and the survival of rabbits after replanting are shown in **Table 3**; the survival rate of rabbits in the control group was only 30%, while the survival rate of

rabbits in the HTK liquid group was 60%, twice that of the control group.

Table 3. Proportion of H&E stained cell area in muscle tissue of severed hind limbs of rabbits (%).

Time (h)	Normal saline group	Cryopreservation group	HTK liquid group	Control group
0	92.35 ± 3.15			
6	75.24 ± 4.16 [#]	55.06 ± 2.46 ^{*#}	60.14 ± 8.34 ^{#*}	42.82 ± 10.05
12	55.45 ± 3.54 [#]	43.66 ± 8.04 [*]	50.02 ± 10.03 [#]	37.30 ± 5.43
18	44.58 ± 5.86	39.86 ± 10.15	50.84 ± 9.24 [#]	35.13 ± 6.08
24	42.82 ± 10.06	37.30 ± 5.45	46.45 ± 6.03 [#]	34.16 ± 6.64

represents comparison with control group ($p < 0.05$), * means compared with normal saline group ($p < 0.05$).

3.2.2. Vascular ultrasound

One surviving rabbit was taken from the HTK liquid group and the control group respectively, and vascular ultrasound was performed on the first day and the first week after surgery (**Figure 14** and **Table 4**), indicating that the femoral arteries and veins of the limbs were unobstructed. Bilateral femoral artery velocity was measured at about 0.5–1 cm above the knee. In the HTK liquid group, the value was 48.9 cm/s on the healthy side and 36.7 cm/s on the replantation side on the first day after surgery. Vascular ultrasound was performed again one week after surgery to measure the flow velocity, with the left side at 60.5 cm/s and the right side at 60.2 cm/s. Control group: On the first day after surgery, the healthy side was 12.8 cm/s, and the replantation side was 8.9 cm/s. One week after the operation, a vascular ultrasound was performed again to measure the flow velocity, the left side was 6.0 cm/s, and the right side was 6.7 cm/s.

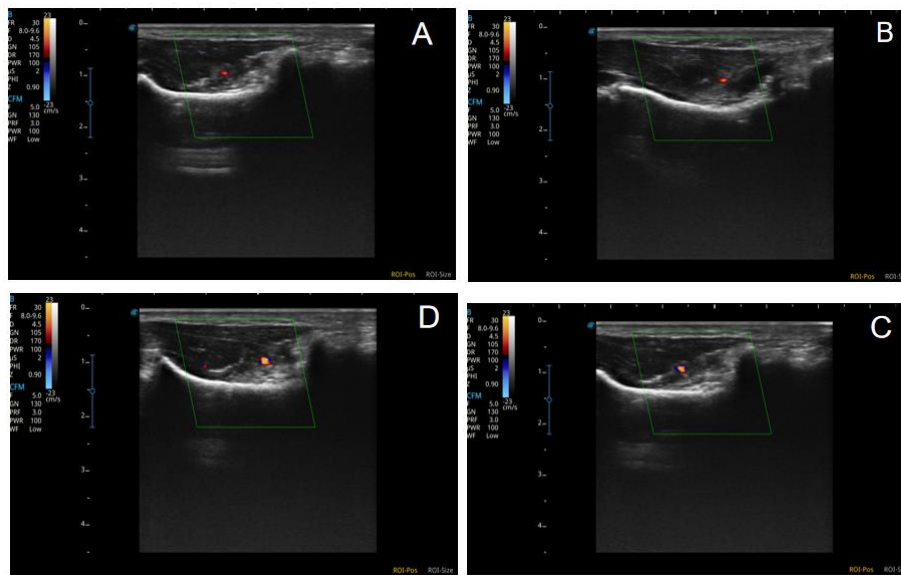


Figure 14. Ultrasound results of femoral artery after grafting of the severed hind limb in rabbit. (A) the left side of the experimental group at the 8th week after surgery; (B) the right side of the experimental group at 8 weeks after surgery; (C) the left side of the control group at 8 weeks after the operation; (D) the right side of control group 8 weeks after surgery.

Table 4. The ischemic time of the severed hind limb and the gross result of replantation in rabbits.

HTK liquid group		Control group	
Ischemic time	Result	Ischemic time	Result
3 h 30 min	Survival	3 h 15 min	The limb was necrotic and fell off spontaneously 8 days after surgery
3 h 40 min	The rabbit died on the first day after surgery	3 h 20 min	The rabbit died on the first day after surgery
3 h 35 min	survival	3 h 30 min	Died the day of surgery.

Table 4. (Continued).

HTK liquid group		Control group	
Ischemic time	Result	Ischemic time	Result
3 h 35 min	The rabbit died on the 3 days after surgery	3 h 40 min	Limb necrosis, rabbit death 2 days after surgery
3 h 50 min	Survival	3 h 30 min	Survival
3 h 45 min	Survival	3 h 35 min	Survival
3 h 40 min	Limb necrosis, rabbit death 5 days after surgery	3 h 50 min	Survival
4 h 0 min	Survival	4 h 20 min	Limb necrosis, rabbit death 3 days after surgery
4 h 10 min	The rabbit died on the 2 days after surgery	4 h 15 min	The rabbit died on the 2 days after surgery
5 h 0 min	Survival	4 h 10 min	The rabbit died on the first day after surgery

3.2.3. H&E staining

The tibialis anterior muscles and nerves of the HTK liquid group and the control group were respectively examined by H&E staining. The results are shown in **Figure 15**: compared with the normal muscles, the basic muscle contour of the control and HTK liquid group remained unchanged after cryopreservation. Compared with the control group, the muscle fiber cross-sectional area of the HTK liquid group did not show any significant difference. In the longitudinal section, the muscle fiber structure of the HTK liquid group and control group showed different degrees of disorder, muscle fiber dissolution and necrosis, but the cell necrosis of the control group was more serious. 24h after replantation, a large number of intramuscular inflammatory cells appeared in the HTK liquid group, while the muscle cells disintegrated and became necrotic. With the extension of reperfusion time, only a small number of myocytes dissolved and necrotic with intramuscular inflammatory cell infiltration occurred one week after replantation.

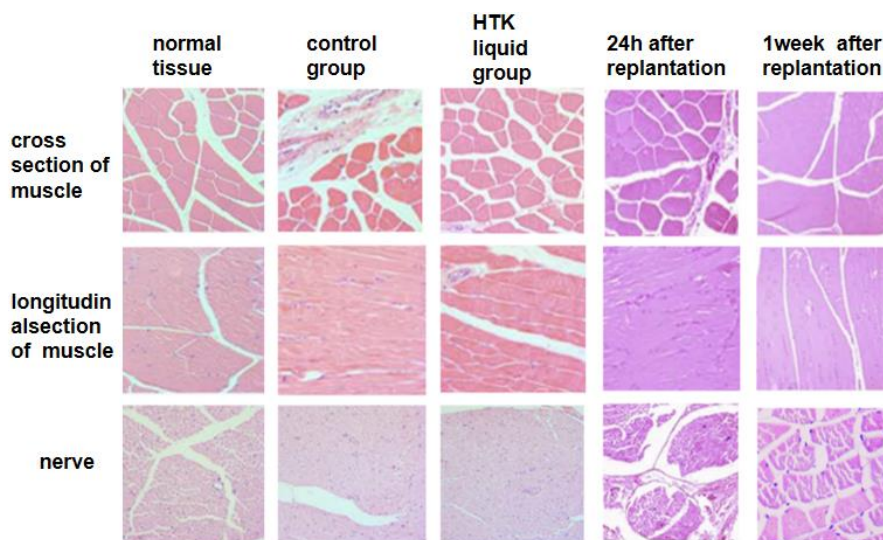


Figure 15. Results of muscle and nerve after replanting of severed hind limbs (H&E stain, 400×).

In addition, in the control group and the HTK liquid group, all the nerves showed axonal degeneration, with no significant difference between the groups. 24h after replantation, inflammatory cell infiltration was observed in the nerve, and the myelin structure in the nerve bundle was disintegrated, destroyed or disorganized. However, 1 week after replantation, no inflammatory cell infiltration was observed in the nerve bundle in the HTK liquid group, only the myelin structure disintegration was observed in the nerve bundle.

3.2.4. TUNEL staining

TUNEL staining was performed on the tibial anterior muscle of the HTK liquid group and the control group, respectively. The results were shown in **Figure 16** compared with the normal muscle, the number of apoptotic cells in the control group was significantly increased. Compared with the control group, the number of apoptotic cells in the HTK liquid group was significantly reduced. Compared with the HTK liquid group, the number of apoptotic cells decreased after 24h replantation. With the extension of time, the percentage of apoptotic cells in the replantation limb decreased significantly after 1 week of replantation and was not much related to the number of normal muscle apoptotic cells.

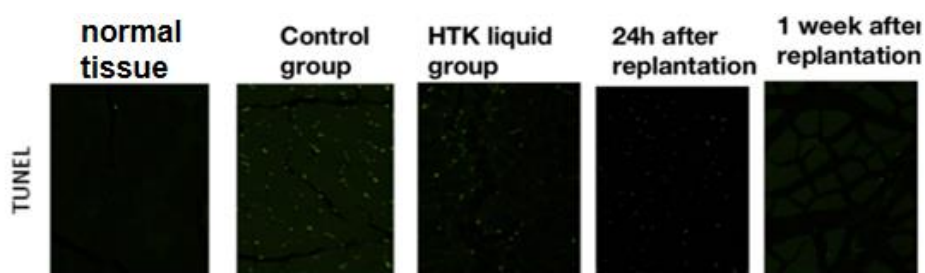


Figure 16. TUNEL staining was used to detect the apoptosis of rabbit muscle cells after replanting of severed hind limbs.

3.2.5. Transmission electron microscope ultrastructure

The ultrastructure of each group was detected by transmission electron microscopy, and the results were shown in **Figure 17**. In the normal group, the myofibrillar fibers in the muscle were neatly arranged, the sarcomere structure was complete, the myofilaments were structured, and the Z line was clear and neat, without obvious damage or dissolution. There are a few mitochondria, and a few cristae can be seen between small myofibrillar fibers, which are evenly distributed along the Z line. In the control group, most myofibrils were still neatly arranged with complete sarcomere structure, and only a few were disordered. The number of mitochondrial aggregation and swelling increased significantly, accompanied by crest fracture or cavitation degeneration. HTK infusion can reduce the disordered arrangement of myofibrils with minor injury. It also protects mitochondria from swelling and vacuolar degeneration. After 24 h replantation, myofibrillar arrangement was disordered, myofilaments were segmental fracture, sarcomere structure was destroyed, and the Z line was chaotic. More mitochondria with clesta-broken or vacuolar degeneration accumulated between myofibrils. In addition, the sarcoplasmic reticulum expanded significantly. After 1 week of replantation, some muscle fibers were disordered and myofilaments were broken segmentally. The number of mitochondria between myofibrils increased with aggregation and extensive swelling. Ridge fracture and cavitation degeneration are seen somewhere. The myomuscular nucleus is in the sub-myomembrane with disordered nuclear membrane arrangement and increased heterochromatin.




Figure 17. Scanning electron microscopy of muscle microstructure after replanting of severed hind limbs of rabbits (1500×).

4. Discussion

Many studies have shown that the main factors affecting the survival rate and functional recovery of severed limb replantations are composed of two parts: ischemic hypoxia injury and reperfusion injury after

circulatory reperfusion. When a limb is severed, circulation immediately stops, various metabolism and oxygen supply are interrupted, and metabolites accumulate, leading to physiological, tissue morphology, and ultrastructural changes, such as cytoplasmic vacuole formation, acidosis, calcium overload, mitochondrial edema. The key to reducing injury is to rebuild the circulation as soon as possible, shorten the ischemic time, and properly preserve the limbs, as energy consumption and reperfusion after rebuilding the circulation will further aggravate tissue damage.

In the 1930s, Allen^[8] discovered for the first time that low-temperature conditions can effectively reduce tissue metabolic activity by studying the effect of temperature on ischemic tolerance in severed limbs. He also pointed out that the optimal temperature should be the lowest temperature that does not cause tissue damage. And it is recommended to use a dry and low-temperature storage method, which is to wrap the severed limb in gauze, seal it in a plastic bag, and then dry and refrigerate it in ice water. This method has been used to this day. Although low temperature can effectively reduce the rate of cellular tissue metabolism and control the process of tissue degeneration, it should be emphasized that low-temperature refrigeration only reduces the speed of cellular metabolic reactions and cannot stop tissue cell metabolism.

Before rebuilding blood circulation, severed limbs should undergo simple, feasible, and cost-effective correct and reasonable preservation, based on prolonging tissue and cell activity, to save time for replantation surgery, reduce ischemia-reperfusion injury, and improve replantation survival rate and postoperative functional recovery. However, due to the complex tissue structure of limbs, different detachment planes, and different environments in which the severed limb is located, there is currently no satisfactory preservation method. At present, in addition to the widely used low-temperature drying and refrigeration method, limb preservation methods also include deep low-temperature freezing preservation, low-temperature perfusion preservation, high-pressure oxygen preservation, and ectopic foster preservation. Each method has its own advantages and disadvantages.

The low-temperature drying and refrigeration preservation method is economically simple and easy to operate, but has a short preservation time limit. Although the whole blood perfusion preservation method with extracorporeal circulation also provides good protection for severed limbs, the use of whole blood may cause side damage to itself, and the operation of extracorporeal circulation is cumbersome and cannot be applied in a timely manner. Deep low-temperature cryopreservation has a good effect on long-term tissue preservation, but cryoprotectants can cause damage to cells during the cooling and rewarming process and have certain cytotoxicity. High pressure oxygen preservation has a certain protective effect on severed limbs, but it requires high preservation requirements and requires the use of specialized vessels, making the operation complex. Although the method of ectopic foster preservation and replantation has solved many severed limbs that cannot be replanted in the first stage, the limb may have slightly poorer functional recovery due to undergoing two replantation surgeries.

Many scholars have studied the application of perfusion fluid based on low-temperature refrigeration preservation to prolong the time limit of limb replantation, which includes organ perfusion fluid, free radical scavenger perfusion fluid, energy mixture perfusion fluid, traditional Chinese medicine formulation perfusion fluid, blood substitutes, and whole blood. Perfusion of limbs with infusion fluid can relieve vascular spasms, dilate vascular lumens, restore the absorption function of capillaries, provide a good vascular foundation for rebuilding blood circulation, and provide basic energy substances for metabolism to tissues through infusion. Maintaining a low metabolic state and maintaining cell membrane stability by effectively flushing out accumulated metabolic products, such as lactic acid in tissues and residual blood and blood clots in blood vessels through perfusion, the absorption of metabolic products by the body after transplantation is reduced, the generation of harmful components such as oxygen free radicals is reduced, and intracellular acidosis and ischemia-reperfusion injury are alleviated.

Organ preservation solutions can be divided into two categories based on the different concentrations of Na⁺ and K⁺ in the preservation solution: intracellular fluid type and extracellular fluid type. Widely used intracellular liquid storage solutions include Euro Collins solution, UW solution, Stanford solution, and HTK solution; Extracellular liquid storage solutions include Celsius solution, St Thomas solution, Ringer's sodium lactate solution, etc.^[9]. The functions of organ preservation solution include: 1) reducing cellular edema that is prone to occur under low-temperature conditions; 2) Reduce the accumulation of acidic substances such as lactic acid and H⁺ produced by anaerobic cell fermentation and glycogen decomposition; 3) Stabilize the intracellular environment and reduce the migration of positive and negative ions across cells; 4) Reduce ischemia-reperfusion injury caused by oxygen free radical damage, calcium overload, etc; 5) Reduce glucose metabolism caused by hypoxia and maintain intracellular Adenosine Triphosphate (ATP) levels; 6) Prevent damage caused by oxygen free radicals^[10]. Many organ transplantation centers use 4 °C physiological saline soaking to preserve donor organs, which can achieve good short-term results (<4 h). However, due to the acidic nature of physiological saline (pH 4.5–4.6), low osmotic pressure (280 mOsm/L), and the absence of high molecular weight colloidal components to balance cell membranes, the long-term effect of soaking alone is poor^[11]. HTK solution is more suitable for organ preservation.

From an ionic perspective, HTK is an isotonic protective liquid with low sodium and slightly high potassium, a small amount of magnesium ions, and a small amount of calcium and chloride ions, with an osmotic pressure of 320 mOsm/L. From the analysis of the buffer system, HTK solution was added with a strong histidine buffer system, with a pH value of 7.2^[12]. Most scholars believe that HTK solution containing histidine buffer can effectively reduce H⁺ aggregation, inhibit acidosis, and increase ATP production rate. From the analysis of antioxidants, HTK solution does not contain any antioxidants. Numerous experiments have shown that adding biological antioxidants such as reducing glutathione, nitroacetylcysteine, catalase, etc. Low-temperature preservation solutions can improve the survival rate of low-temperature preserved cells and alleviate reperfusion injury and cell apoptosis caused by the generation of large amounts of oxygen free radicals in cells after rewarming^[10]. From the analysis of energy substrates, the HTK solution is characterized by α -Ketoglutarate (an intermediate product in the tricarboxylic acid cycle)^[11] and tryptophan (a precursor of nicotinamide nucleotide coenzyme (NAD⁺/NADP))^[13] promote ATP synthesis through the tricarboxylic acid cycle during low-temperature preservation of skeletal muscle cells^[12,14].

Under normal conditions, skeletal muscle cells contain a large number of enzymes such as ALP, ALT, AST, LDH, CK, etc. The membrane pore diameter of skeletal muscle cells is 3–4 nm, while the diameter of these enzyme protein molecules is between 50–200 nm, which is larger than the membrane pore diameter of muscle cells. So when the cell structure is not damaged, only a small amount of enzyme proteins will permeate from the cell membrane^[15]. When a limb is severed, ischemia causes damage to skeletal muscle cells, cell membranes rupture, and a large amount of enzymes are released into the blood. Therefore, changes in ALP, ALT, AST, LDH, and CK content can be measured to reflect the degree of cell damage^[16–20]. SOD can effectively eliminate oxygen free radicals, reflect the body's antioxidant capacity, and is an indicator of oxidative damage^[21,22]. O₂⁻ can cause apoptosis of vascular smooth muscle and skeletal muscle through the oxidation of low-density lipoprotein. SOD, as the first line of defense in the system for clearing oxygen free radicals in the body, catalyzes the dismutation of O₂⁻ into H₂O₂ and O₂^[23]. And H₂O₂ is converted into H₂O and O₂ under the action of peroxidase. Through this method, SOD clears O₂⁻ and becomes a harmless product. Glucose (GLU) is an important substance in the body's glucose metabolism and a major energy source. Lactic acid (LAC) is the final product of anaerobic glycolysis. When ischemia and oxygen supply stop in the severed lower limbs, the normal aerobic oxidation pathway of the body is interrupted, and the cessation of the tricarboxylic acid cycle leads to a rapid decrease in ATP production as a direct energy source. Muscles can only obtain the required ATP by unilaterally strengthening the glycolytic pathway. This leads to a significant decrease in GLU content, while the content of LAC, a product of glycolysis, increases^[24]. The accumulation

of LAC within an organization can cause cellular acidosis and affect cellular activity^[25].

Experimental studies have confirmed that the main form of skeletal muscle death in ischemia and ischemia-reperfusion injury is cell apoptosis^[26]. The Bax gene belongs to the Bcl-2 family, which includes two major categories: one is apoptotic precursor proteins (such as Bax, Bad, and Bak proteins), and the other is anti-apoptotic proteins (such as Bcl-2, Bcl-xl, and Mcl-1 proteins). Bcl-2 and Bax are closely related to cell apoptosis. The interaction between the two is reflected at the mitochondrial level, and regulation related to mitochondria is an important aspect of it^[27]. Bcl-2 inhibits cell apoptosis by stabilizing the function of mitochondrial membranes^[28]. And Bax combines with Bcl-2 to form a dimer, which promotes apoptosis by inhibiting the activity of Bcl-2^[29]. The studies of Li et al.^[30] and Pan et al.^[31] suggest that when death information is conveyed to the Bax in the cytoplasm, the mitochondrial membrane forms a Bax channel, which releases cytochrome C into the cytoplasm and induces cell apoptosis. Bax shifts to the mitochondria after receiving death signals such as cytotoxicity, ischemia, and hypoxia stimuli. In fact, the absence of carboxyl terminus prevents Bax translocation, thereby inhibiting apoptosis, suggesting that regulation related to mitochondrial membrane is an important stage in the transmission of apoptosis signals^[17].

Transmission electron microscopy can observe the structure of organelles and plays a crucial role in determining muscle tissue degeneration. The irreversible degeneration of skeletal muscle cells observed under electron microscopy is characterized by muscle filament breakage, mitochondrial vacuolization, cristae rupture or disappearance, and nuclear pyknosis and rupture. Mitochondria are organelles within cells that are more sensitive to pathogenic factors, and they are the site for oxidative respiration and energy production in cells. Therefore, morphological changes in mitochondria are often used as indicators of cellular hypoxia damage. The degeneration, dissolution, and disappearance of mitochondria indicate cell death^[32]. The general morphological characteristics of apoptotic cells under electron microscopy are reduced cell volume, deep staining of cytoplasm, condensation of nuclear chromatin, intact bilateral nuclear and cytoplasmic membranes, and occasional formation of vacuoles in the cytoplasm. In apoptotic cells, it can be seen that heterochromatin in the nucleus is significantly condensed under the nuclear membrane. Some apoptotic cells have chromatin condensed around the nucleus in a crescent shape, which is more common and typical and is usually described as "chromatin edge shift"^[33].

It can be seen from the various detection methods in the part of the experiment that the tissue damage is gradually aggravating with the extension of time. In the gross view, the tissue of the severed limb perfusion group was moist, and there were different degrees of limb swelling, especially in the normal saline group. In the blank group, there was no swelling. Biochemical tests showed that ALP, ALT, AST, CK and LDH, which represented the degree of cell damage, gradually increased with time, GLU, which was related to energy metabolism, gradually decreased, LAC increased, and SOD, which represented oxidative damage, gradually decreased. In the HTK group, the indexes representing cell damage were the lowest at each time point, GLU was the highest, and LAC was the lowest. Although the HTK liquid did not contain oxygen-free radical scavengers, the SOD content in the HTK group was the lowest, suggesting that HTK also had antioxidant effects. The other three groups had no exogenous oxygen-free radical scavenger, and the oxidative damage was more serious. All of these indicate that the HTK solution is more suitable for limb perfusion and refrigerated preservation in terms of biochemical detection results.

It is difficult to explain the final effect of an in vivo experiment by simply preserving the severed limb and not replanting it. So, we refer to part of the literature^[34-36]. Two parts of the experiment are designed. In the pre-experiment, immediate implantation after disconnection, whether perfusion or not, can survive. Therefore, we tried the effect of replantation with different ischemic time and found that both the experimental group and the control group died after 6h, the cause of death was unknown, but both groups survived within 3 h. We speculated that the possible causes of animal death were long time of wound exudation, increased injury after several hours of surgery, time of exposure, inability to rehydrate, etc. Rabbits had poor tolerance to large

wounds and were prone to hypovolemic shock and death, rather than completely caused by the factors of limb replantation itself. Therefore, the time of limb replantation of small animals is limited by the degree of tolerance to the trauma of the whole body, and the ischemia time can only be limited to 3–5 h in this experiment.

The purpose of this experiment is to observe the HTK solution which is selected in experiment 1 and has the best preservation effect on the amputated limb and verify whether it has a good effect on the limb survival after replanting. The gross results of replanting confirmed that the survival rate of replanting of the limbs after a one-time infusion of HTK solution with low-temperature refrigeration was higher than that of replanting with cold storage alone. The survival rate of the experimental group was 60% (6/10). The survival rate of the control group was only 30% (3/10). The survival rate of the experimental group was twice that of the control group. After survival, observation at 2 weeks after surgery showed that hair grew out of the replanted limbs and the skin incision healed well. The sutures were cut off by oneself, and there was no obvious skin necrosis. There were 2 cases of local anastomotic nonunion (about 0.5 cm in length) and purulent exudation in the wound, which recovered well after debridement and suture. We assume it was a local infection. The limb has no motor function but can be used as an auxiliary leg when upright.

Postoperative pathological results showed that no matter the experimental group or the control group, postoperative survival or non-survival, there was many inflammatory cell infiltration in the limbs after surgery. For the surviving limbs, cells in the experimental group were more orderly than those in the control group, cell and interstitial edema was less, and cell damage was also less than that in the control group. For the limbs that did not survive, the control group had a large number of red blood cells in the muscle space, and the congestion of the limbs was more obvious than that of the experimental group, but there was little difference in the degree of cell damage between the two groups. This indicates that the application of HTK liquid perfusion can not only improve the survival rate of replantation surgery but also have a significant easing effect on postoperative ischemia and hypoxia injury of surviving limbs. 0.5–1 cm above the knee corresponds to 0.5–1 cm below the vascular anastomosis. Blood flow signals could be detected 0.5 cm above the knee on the second day and 8 weeks after surgery, indicating that the vascular anastomosis above was unobstructed. On the second day after surgery, the blood flow velocity on the operative side was about 10 m/s slower than that on the opposite side. At 10 weeks, there was no significant difference in blood flow velocity between the two sides. However, the position of the blood flow signal detected by ultrasound is not constant and has great variation. Therefore, there was a large difference in postoperative blood flow velocity between the control group and the experimental group.

Finally, this animal experiment verified that the process of tissue degeneration was delayed after HTK solution was injected and stored in cold storage, the preservation time of the activity of severed limbs was prolonged, tissue damage caused by ischemia and hypoxia was reduced, and the survival rate of reimplanted limbs was improved.

5. Conclusion

Combined with a light microscope, electron microscope and extracted biochemical indicators, it can be found that the perfusion solution HTK solution can play a protective role in the severed limb, prolong the cell activity time, and the protective effect on the limb is stronger than the use of normal saline perfusion and cryopreserved. Although the specific use of HTK infusion is limited due to its high price, it has a protective effect on severed limbs, prolonging cell activity and other functions, so it can replace cryopreservation in the implementation of severed limb perfusion.

Author contributions

Writing—review and editing, SZ; conceptualization, SO and BE; supervision, SL. All authors have read and agreed to the published version of the manuscript.

Funding

The research was supported by the 2022 Plan of Health Science and Technology of Inner Mongolia Autonomous Region of China (No.202202273) and Inner Mongolia Autonomous Region Natural Science Fund Management Information System Public Service Platform (2023LHMS08033).

Conflict of interest

The authors declare no conflict of interest.

References

1. Krezdorn N, Sakthivel D, Turk M, et al. Reduced Hypoxia-Related Genes in Porcine Limbs in Ex Vivo Hypothermic Perfusion Versus Cold Storage. *Journal of Surgical Research*. 2018; 232: 137-145. doi: 10.1016/j.jss.2018.05.067
2. Kueckelhaus M, Dermietzel A, Alhefzi M, et al. Acellular Hypothermic Extracorporeal Perfusion Extends Allowable Ischemia Time in a Porcine Whole Limb Replantation Model. *Plastic & Reconstructive Surgery*. 2017; 139(4): 922e-932e. doi: 10.1097/prs.0000000000003208
3. Ozer K. Advances in Limb Preservation: From Replantation to Transplantation. *The Journal of Hand Surgery*. 2020; 45(7): 626-637.e5. doi: 10.1016/j.jhssa.2020.04.006
4. Lindell SL, Compagnon P, Mangino MJ, et al. UW Solution for Hypothermic Machine Perfusion of Warm Ischemic Kidneys. *Transplantation*. 2005; 79(10): 1358-1361. doi: 10.1097/01.tp.0000159143.45022.f6
5. Wei J, Chang CY, Chuang YC, et al. Successful Heart Transplantation After 13 Hours of Donor Heart Ischemia With the Use of HTK Solution: A Case Report. *Transplantation Proceedings*. 2005; 37(5): 2253-2254. doi: 10.1016/j.transproceed.2005.03.055
6. Wilson CRH, Brook N, Talbot D. Preservation Solutions for Solid Organ Transplantation. *Mini-Reviews in Medicinal Chemistry*. 2006; 6(10): 1081-1090. doi: 10.2174/138955706778560148
7. Jamieson RW. Organ reperfusion and preservation. *Frontiers in Bioscience*. 2008; 13(13): 221. doi: 10.2741/2672
8. Allen FM. Resistance of peripheral tissue to asphyxia at various temperature. *Surg Gynec Obstet*. 1938; 67: 746-749.
9. Gao D, Li Q, Zhang Q, et al. Comparison of the effects of UW solution, Celsius solution, and HTK solution on low-temperature preservation of L-02 cells for bioartificial live. *Guangdong Medical Journal*. 2011; 32 (08): 962-965. doi: 10.13820/j.cnki. gdyx. 2011.08.029
10. Hachida M, Lu H, Ohkado A, et al. Effect of ATP-potassium channel opener nicorandil on long-term cardiac preservation. *Journal of Cardiovascular Surgery*. 2000; 41(4): 533.
11. Guha M, Kumar S, Choubey V, et al. Apoptosis in liver during malaria: role of oxidative stress and implication of mitochondrial pathway. *The FASEB Journal*. 2006; 20(8): 1224-1226. doi: 10.1096/fj.05-5338fje
12. Jia X, Yang H. Effect of various methods of tissue storage on split-skin viability at 4 °C. *Chinese Journal of Surgery*. 1998; 36(011): 694-696.
13. Kober IM, Obermayr RP, Brüll T, et al. Comparison of the Solutions of Bretschneider, St. Thomas' Hospital and the National Institutes of Health for Cardioplegic Protection during Moderate Hypothermic Arrest. *European Surgical Research*. 1998; 30(4): 243-251. doi: 10.1159/00008583
14. Başaran Ö, Özdemir H, Kut A, et al. Effects of different preservation solutions on skin graft epidermal cell viability and graft performance in a rat model. *Burns*. 2006; 32(4): 423-429. doi: 10.1016/j.burns.2005.11.010
15. Li Y. Diagnostic significance analysis of serum transaminase and creatine kinase measurements in patients with skeletal muscle diseases. *Chinese and Foreign Medical Journal*. 2014; 33(21): 23-25. doi: 10.16662/j.cnki.1674-0742.2014.21.051
16. Yan C, Qu SL, Wang J, Zou JN. Effect of adrenomedullin on skeletal muscle ischemia/reperfusion injury in rats. *Journal of Clinical Rehabilitative Tissue Engineering Research*. 2009; 13(2): 292-295.
17. Shang G, Guo X, Wang D, et al. The effect of cervical sympathetic nerve block on skeletal muscle ischemia-reperfusion injury. *Chinese Journal of Modern Medicine*. 2014; 24(29): 18-22.
18. Yan C, Qu S, Wang J, Zou J. The effect of adrenomedullin on skeletal muscle ischemia-reperfusion injury. *Chinese Journal of Tissue Engineering Research and Clinical Rehabilitation*. 2009; 13(2): 292-295.
19. Baird MF, Graham SM, Baker JS, et al. Creatine-Kinase- and Exercise-Related Muscle Damage Implications for Muscle Performance and Recovery. *Journal of Nutrition and Metabolism*. 2012; 2012: 1-13. doi: 10.1155/2012/960363
20. Xu C, Gao Y, Liang S. The function and diseases of P2 receptors in skeletal muscle. *Chinese Pharmacological Bulletin*. 2010; 26(2): 144-147.
21. Wan F, Zhao X, Liu B, Li J. Study on the protective effect of ligustrazine on myocardial ischemia-reperfusion injury in rats. *Chinese Journal of Clinical Pharmacology and Therapeutics*. 1998; 3: 184-186.
22. Chen W, Liu N, Zhang Y, et al. Exogenous hydrogen sulfide protects against myocardial injury after skeletal

- muscle ischemia/reperfusion by inhibiting inflammatory cytokines and oxidative stress in rats. *Journal of Southern Medical University*. 2013; 33(4): 554-558.
23. Lancerotto L, Tocco I, Salmaso R, et al. Necrotizing fasciitis. *Journal of Trauma and Acute Care Surgery*. 2012; 72(3): 560-566. doi: 10.1097/ta.0b013e318232a6b3
 24. Zhou F. Pathophysiology of tissue blood perfusion and microcirculation - Oxidative stress and diseases. *Surgical Theory and Practice*. 2007; 6: 625-632.
 25. Wang G, Li R, Zhang Z, et al. The effect of temperature on irreversible degeneration of rabbit skeletal muscle cells. *Journal of Jilin University (Medical Edition)*. 2002; 5: 501-503. doi: 10.13481/j.1671-587x.2002.05.026
 26. Ikeda H, Suzuki Y, Suzuki M, et al. Apoptosis is a major mode of cell death caused by ischaemia and ischaemia/reperfusion injury to the rat intestinal epithelium. *Gut*. 1998; 42(4): 530-537. doi: 10.1136/gut.42.4.530
 27. Capano M, Crompton M. Bax translocates to mitochondria of heart cells during simulated ischaemia: involvement of AMP-activated and p38 mitogen-activated protein kinases. *Biochemical Journal*. 2006; 395(1): 57-64. doi: 10.1042/bj20051654
 28. Fiskum G. Mitochondrial Participation in Ischemic and Traumatic Neural Cell Death. *Journal of Neurotrauma*. 2000; 17(10): 843-855. doi: 10.1089/neu.2000.17.843
 29. Chen CJ, Cheng FC, Liao SL, et al. Effects of naloxone on lactate, pyruvate metabolism and antioxidant enzyme activity in rat cerebral ischemia/reperfusion. *Neuroscience Letters*. 2000; 287(2): 113-116. doi: 10.1016/S0304-3940(00)01151-4
 30. Li P, Deepak N, Imawati B, et al. Cytochrome c and dATP-Dependent Formation of Apaf-1/Caspase-9 Complex Initiates an Apoptotic Protease Cascade. *Cell*. 2004; 116: 479-489.
 31. Pan Dixit G, O'Rourke K, Vishva. *Cell Biology and Metabolism: Caspase-9, Bcl-XL, and Apaf-1 Form a Ternary Complex*.
 32. Wang G, Wang G, Xu Z. Experimental study on the dynamic changes of GPT, ALP, and Glu in skeletal muscle of ischemic human body at room temperature. *Journal of Norman Bethune Medical University*. 1999; 5: 632-633. doi: 10.13481/j.1671-587x.1999.05.044
 33. Shen Q, Yu Z, Fa J, et al. Morphological characteristics of several apoptotic cells under electron microscopy. *Journal of Fudan University (Medical Edition)*. 2010; 37(3): 322-325.
 34. Hettiaratchy S, Randolph MA, Andrew Lee WP. Long-term consideration of hand transplantation. *Transplantation*. 2003; 75(9): 1605. doi: 10.1097/01.tp.0000059447.40513.fb
 35. Atkins SE, Winterton RIS, Kay SP. (v) Upper limb amputations: Where, when and how to replant. *Current Orthopaedics*. 2008; 22(1): 31-41. doi: 10.1016/j.cuor.2008.02.001
 36. Lloyd MS, Teo TC, Pickford MA, et al. Preoperative management of the amputated limb. *Emergency Medicine Journal*. 2005; 22(7): 478-480. doi: 10.1136/emj.2003.008797