

## REVIEW ARTICLE

# Hydroxychloroquine for the treatment of cutaneous lupus erythematosus

Fukumi Furukawa\*

Takatsuki Red Cross Hospital, Abuno 1-1-1, Takatsuki, Osaka 569-1096, Japan. E-mail: [ffurukawa@takatsuki.jrc.or.jp](mailto:ffurukawa@takatsuki.jrc.or.jp)

Running title: Hydroxychloroquine for cutaneous lupus erythematosus

---

## ABSTRACT

In recent years of immunology, the understanding of innate immunity has deepened, and the concept of innate immunity has been proposed even in the area of acquired immune subjects. The conventional immunosuppressive treatments have mainly controlled the step of acquired immunity. However, the involvement of innate immunity was clarified for hydroxychloroquine (HCQ), which has been confirmed to be very effective for cutaneous lupus erythematosus (CLE). This review introduces the mechanism of development of CLE from the viewpoint of autoantibodies, cytokines, and innate immunity. Furthermore, the mechanism of HCQ is introduced and discussed.

**Keywords:** Hydroxychloroquine; Innate Immunity; Cutaneous Lupus Erythematosus; Systemic Lupus Erythematosus; Treatment; COVID-19

---

## ARTICLE INFO

---

### Article history:

Received 6 June 2021

Received in revised form 26 June 2021

Accepted 8 July 2021

Available online 8 July 2021

## COPYRIGHT

---

Copyright © 2021 Fukumi Furukawa.

doi:10.24294/ti.v5.i1.1269

EnPress Publisher LLC. This work is licensed under the Creative Commons Attribution-NonCommercial 4.0 International License (CC BY-NC 4.0).

<http://creativecommons.org/licenses/by/4.0/>

## 1. Introduction

Hydroxychloroquine sulfate (HCQ) is the world standard treatment for cutaneous lupus erythematosus (CLE) and systemic LE (SLE). In Japan, HCQ could not be administered due to the frequent appearance of severe side effects for a long time<sup>[1]</sup>. It was later discovered that the high frequency of severe side effects was due to the wrong administration method.

The Japan Hydroxychloroquine Study Group was established with Drs. Furukawa F, Yokogawa N and Yamamoto K as the main members, and several case reports were published<sup>[2,3]</sup>. Furthermore, the usefulness of HCQ was confirmed in autoimmune-prone MRL/l mice with skin lesions<sup>[4,5]</sup>. In 2017, a multicenter, double-blind, randomized, parallel-group trial in Japan reported effectiveness of HCQ in patients with CLE<sup>[6]</sup>. About a year and a half before this publication, HCQ could be used in Japan for the treatment of CLE and SLE from September 2015, which was officially approved by the Japanese Ministry of Health, Labor and Welfare. Furthermore, since this drug sometimes causes serious side effects such as retinal degeneration, a guide for proper use has also been published<sup>[7]</sup>. In addition, HCQ was reported to be effective against the new coronavirus infection (COVID-19), so it attracted a lot of attention<sup>[8]</sup>.

This paper introduces clinical trials on HCQ characteristics, usage for CLE, clinical effects, precautions for use, side effects, etc.

## 2. Mechanism of onset of skin lupus erythematosus from the viewpoint of innate immunity

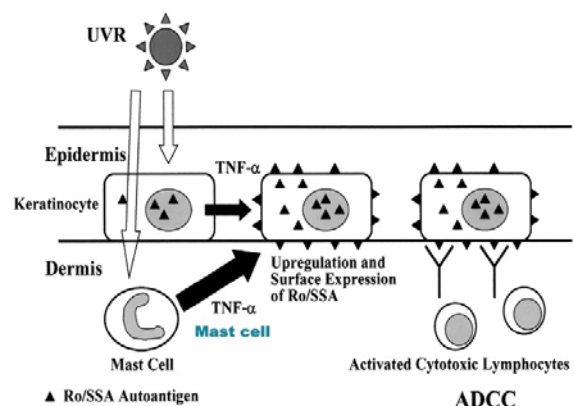
Well-known mechanisms include the involvement of antibody-dependent cellular cytotoxicity (ADCC) targeting SS-A/Ro antigens<sup>[9,10,11]</sup> and the cytokine and/or chemokine network model described below<sup>[12,13]</sup>.

### 2.1 From the perspective of autoantibodies

The serological feature of SLE is the presence of autoantibodies. It is still hard to say that the role of anti-DNA antibodies is elucidated in skin lesions, except for their involvement in renal lesions. On the other hand, it became clear from clinical and research aspects that there is a strong relationship between photosensitivity of subacute CLE (SCLE) and neonatal LE (NLE) and serum anti-SS-A/Ro antibody. It has become a research model for photosensitivity<sup>[9,10]</sup>. A typical model is ADCC, which targets SS-A/Ro antigens. When cultured epidermal cells derived from normal adult or neonatal foreskin are irradiated with ultraviolet light B (UVB), the antigen is translocated and up-regulated on the cell surface, and anti-60 kD/Ro antibody and anti-52 kD/Ro antibody are bound

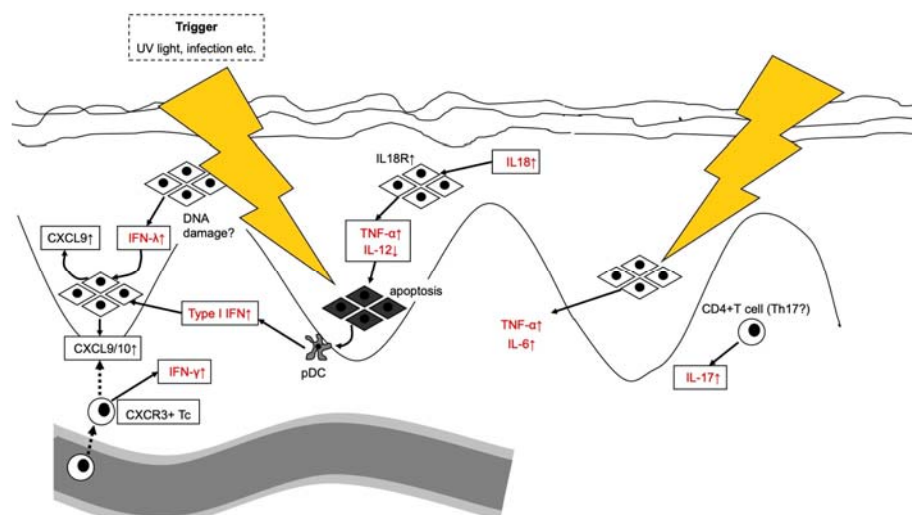
to induce ADCC. A similar tendency is observed in cultured epidermal cells derived from patients<sup>[9]</sup>.

The mechanism by which autoantibodies move into cells and bind to the corresponding antigens has been a problem/question, but the movement of the antigen due to stimuli such as UV lights (UVLs) causes binding<sup>[14]</sup>. It was important that the antigen moved to the surface, not the antibody. This phenomenon is induced not only by UVLs but also by changes in temperature and external factors such as under heat shock protein induction<sup>[11]</sup> (See **Figure 1**).



**Figure 1.** Ultraviolet radiation (UVR) induces antibody dependent cellular cytotoxicity (ADCC) model targeting SS-A/Ro antigen which is mediated by transfer necrosis factor (TNF)  $\alpha$  from mast cells (10,11,14).

### 2.2 From the viewpoint of cytokines



**Figure 2.** Involvement of cytokines in CLE (Mikita's model).

Discoid LE (DLE), which is a typical disease of chronic CLE (CCLE), has an antinuclear antibody

positive rate of about 50%. The rate of disease specific autoantibody is extremely low, and no ADCC is

observed. However, because eruptions often occur in sun-exposed areas and characteristic skin lesions from clinical and pathological features, DLE patients have a different mechanism from the pathogenesis of acute CLE (ACLE) in SLE patients<sup>[15,16]</sup>. Cytokines such as TNF $\alpha$  and IL-12 and infiltrating cells have been shown to be important in photosensitivity. The same applies not only to DLE but also to LE (mainly CCLE) that does not have disease-specific autoantibodies (See **Figure 2**).

### 2.3 Involvement of innate immunity

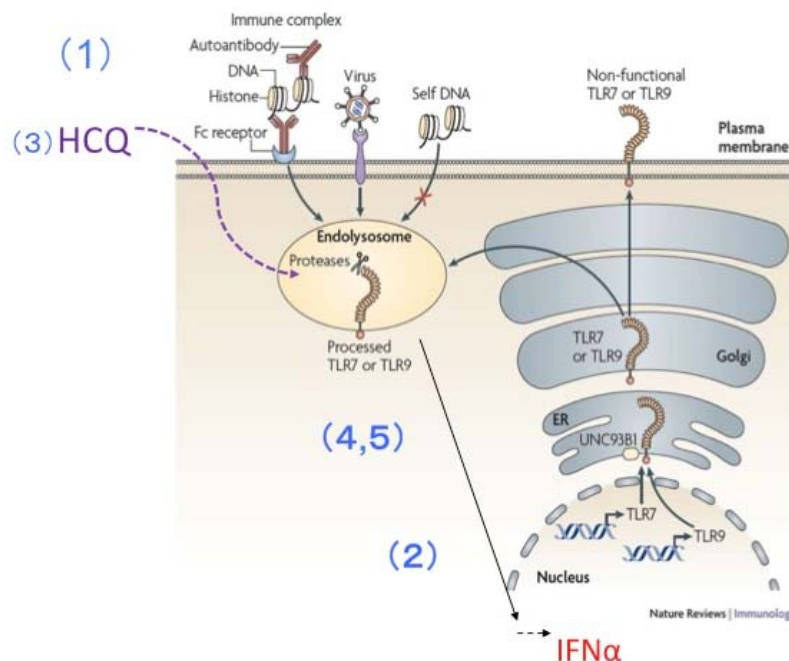
In recent years of immunology, the understanding of innate immunity has deepened, and at the same time, the concept of innate immunity has been proposed even in the area of acquired immune subjects<sup>[17]</sup>.

Wenzel proposed an innate immunity-acquired immune cycle model in CLE onset<sup>[18]</sup>. Genetic predisposition including IFN regulation, antigen presentation, and immune complex removal, first exists and then involvement of environmental factors such as UVLs, tobacco, and drugs begins to drive the unbalanced immune cycle. Then the loop cycle be-

gins to rotate for completion of CLE, in which several mechanisms are involved such as innate immunity (IFN activation, inflammatory cytokine production, activation of complement system activation), acquired immunity (activation of cytotoxic cells, antigen presentation, autoantibody production), histological completion of skin lesions and amplification of auto-reaction phenomenon (release of nucleic acid components, activation of keratinocytes, activation of pDC, etc.).

This concept clarified and made it easier to understand the relationship with treatment methods involved in immunity. The conventional immunosuppressive treatments have mainly controlled the step of acquired immunity in systemic treatments. A recent paper by Sim *et al.*<sup>[19]</sup> has the interpretation from a similar new perspective. In addition, Nakajo Nishimura Syndrome suggests the involvement of autoinflammation in the development of LE-like lesions<sup>[20,21,22]</sup>.

### 3. Action mechanisms of hydroxychloroquine



**Figure 3.** Possible mechanism of action of HCQ (There are some modifications by the author, from ref. 24). (1) Nucleic acids that are continuously present in excess are processed by dendritic cells as autoantigens. (2) IFN $\alpha$  overproduction mediated by TLR7, 9. (3) Administration of HCQ. (4) Positively charged and accumulated in lysosomes to change pH and inhibits the step 2. (5) Then it inhibits the immune response to self-antigens, but does not impair the response to foreign antigens, so it exhibits immunomodulatory effects without immunosuppression.

HCQ is an old and new drug. It has a long history of use, and it is only recently that one of its

mechanisms has been clarified from the perspective of immunity<sup>[23]</sup>. This drug has a wide range of ac-

tions such as anti-inflammatory action, immunomodulatory action, antimalarial action, and antitumor action. Although multiple mechanisms of action have been proposed, basic studies of innate immunity have revealed an inhibitory effect on innate immune disorders.

In SLE, excess apoptosis cell-derived nucleic acids are expected to form and stabilize immune complexes with autoantibodies and to be persistently presented. They are processed by dendritic cells and binds to Toll-like receptors 7 and 9 in lysosomes, resulting in overproduction of IFN $\alpha$ . HCQ accumulates in lysosomes, changes pH, and inhibits Toll-like receptor-mediated IFN $\alpha$  production and dendritic cell maturation. This mechanism has no immunosuppressive effect and exhibits an immunomodulatory effect<sup>[24]</sup> (**Figure 3**). HCQ is understood to have excellent therapeutic effects by controlling the first step in Wenzel cycle<sup>[18]</sup>: innate immunity, such as IFN activation, inflammatory cytokine production, and complement system activation.

#### 4. What kind of patients are targets?

1) For CLE patients with only localized skin symptoms, when topical preparations such as corticosteroids are inadequately effective or when the use of external preparations is inappropriate.

2) For SLE patients in whom skin lesions exist including malaise, musculoskeletal symptoms, etc.

(These are cited from reference 7 that was published for Japanese physicians)

#### 5. Clinical data evidence and problems of hydroxychloroquine

For Japanese patients diagnosed with CLE with or without SLE, 200 to 400 mg of this drug (not to exceed 6.5 mg/kg in ideal body weight) is orally administered once daily for efficacy and safety. As described in our previous reports<sup>[6,7]</sup>, HCQ was found to be effective against active skin lesions. In SLE patients, RAPID3 (daily life activity, muscle or joint pain due to primary disease [VAS], severity due to primary disease evaluated by patients [VAS]), and malaise VAS were all statistically significant for improvement 16 weeks after administration in

the HCQ group<sup>[6]</sup>.

According to a recent post-marketing surveillance (September 7, 2015 - April 18, 2020), the efficacy rates for skin lesions in 331 patients after 16 and 52 weeks were 41.7% and 49.9%, respectively. Side effects were observed in 159 cases (15.8%) out of 1007 cases subject to safety analysis, and serious side effects appeared in 17 cases (1.7%). From almost the same analysis, serious side effects included 6 severe skin disorders (2 cases of erythema multiforme and 4 cases of toxic derma or eruption) and 4 cases of eye disorders (posterior capsule opacity, retinal pigment epithelium, retinopathy, and retinal pigment epithelial detachment)<sup>[25]</sup>. In terms of frequency of occurrence, drug eruption and rash are the most common, followed by diarrhea and other gastrointestinal symptoms.

A systematic review by Sharma *et al.*<sup>[26]</sup> revealed that drug eruption or rash (358 cases) was the most common, and hyperpigmentation of the skin (116 cases), pruritus (62 cases), and acute generalized exanthematous pustulosis or -like disease (27 cases), Stevens-Johnson syndrome or toxic epidermal necrolysis (26 cases), hair loss (12 cases), and stomatitis (11 cases) have been reported. The nomenclature of skin lesions is not always unified in the world. Most of the drug eruptions developed within 4 weeks after the start of HCQ administration and disappeared within a few weeks after discontinuation. It is not necessary to decrease or discontinue for patients with drug eruption up to moderate diseases that do not other organs' problems<sup>[27,28]</sup>.

Retinal degeneration is the most notable side effect of HCQ. Petri M *et al.* states that it is important to monitor the blood concentration of HCQ<sup>[29]</sup>, but since the onset of retinopathy of HCQ involves multiple factors including genetic background such as race, and the significance of blood concentration, it will be investigated in the future<sup>[30,31,32]</sup>.

#### 6. Trends and future prospects in the treatments of CLE

Regarding HCQ, the algorithms suitable for Japanese or Asian people was proposed who still

have some restrictions on drugs to be administered<sup>[6,33]</sup>, but there are many important issues to be clarified such as the selection of the type of skin lesions for which HCQ is effective or not<sup>[2,34,35]</sup>, effects of combination therapy<sup>[36,37]</sup> and more sensitive and early diagnostic methods for retinal degeneration<sup>[29,30,31,32]</sup>.

On the other hand, due to the limited number of treatments for CLE, several new drugs are being developed. Some recent trials are introduced<sup>[37]</sup>. BI-IB059 is an antibody that targets IFN, and Anifrolumab is also an antibody against type I interferon receptor, both of which have been excellently reported in the interim report. Iberdomide is positioned as an immunomodulator and exerts its medicinal effect by binding to cereblon (CRBN), which is a component of the substrate receptor<sup>[38]</sup>. With the launch of these new drugs, great expectations are placed on the wide range of treatment options.

## Appendix

HCQ was taken up as a treatment for the pandemic new coronavirus in the early stages of exploring treatments. There is a background that HCQ also has an antiviral effect against the coronavirus that causes emerging infectious diseases<sup>[8]</sup>. It has been found to have in vitro activity against SARS-CoV-2 and had come to be mainly used in the United States as a drug expected to be effective against COVID-19, but its efficacy was not determined. Recent papers or reports denied the usefulness of HCQ to COVID-19<sup>[39]</sup>.

## Conflict of interest disclosure

None declared

## Acknowledgments

Finally, we would like to thank Professor Toshikazu Kondo and Mariko Kawaguchi of the Department of Forensic Medicine, Wakayama Medical University for their encouragement and support in scientific discussions and literature searches.

## References

1. Furukawa F. Practical therapeutics for skin lesions of Japanese patients with discoid lupus erythematosus. *Expert Opinion on Orphan Drugs* 2014; 2(5):

- 477–482. doi: 10.1517/21678707.2014.901166
2. Ikeda T, Kanazawa N, Furukawa F. Hydroxychloroquine administration for Japanese lupus erythematosus in Wakayama: A pilot study. *The Journal of Dermatology* 2011; 39(6): 531–535. doi: 10.1111/j.1346-8138.2011.01448.x
3. Yokogawa N, Tanikawa A, Amagai M, *et al.* Response to hydroxychloroquine in Japanese patients with lupus-related skin disease using the cutaneous lupus erythematosus disease area and severity index (CLASI). *Modern Rheumatology* 2013; 23(2): 318–322. doi: 10.1007/s10165-012-0656-3
4. Furukawa F, Tanaka H, Sekita K, *et al.* Dermatopathological studies on skin lesions of MRL mice. *Archives of Dermatological Research* 1984; 276: 186–194. doi: 10.1007/BF00414018
5. Shimomatsu T, Kanazawa N, Mikita N, *et al.* The effect of hydroxychloroquine on lupus erythematosus-like skin lesions in MRL/lpr mice. *Modern Rheumatology* 2016; 26(5): 744–748. doi: 10.3109/14397595.2016.1140711
6. Yokogawa N, Eto H, Tanikawa A, *et al.* Effects of hydroxychloroquine in patients with cutaneous lupus erythematosus: A multicenter, double-blind, randomized, parallel-group trial. *Arthritis & Rheumatology* 2017; 69(4): 791–799. doi: 10.1002/art.40018
7. Furukawa F, Eto H, Tanikawa A, *et al.* Guide to proper use of hydroxychloroquine. *The Japanese Journal of Dermatology* 2015; 125(11): 2049–2060. doi: 10.14924/dermatol.125.2049
8. Wang M, Cao R, Zhang L, *et al.* Remdesivir and chloroquine effectively inhibit the recently emerged novel coronavirus (2019-nCoV) in vitro. *Cell Research* 2020; 30: 269–271. doi: 10.1038/s41422-020-0282-0
9. Furukawa F, Itoh T, Wakita H, *et al.* Keratinocytes from patients with lupus erythematosus show enhanced cytotoxicity to ultraviolet radiation and to antibody-mediated cytotoxicity. *Clinical & Experimental Immunology* 1999; 118(1): 164–170. doi: 10.1046/j.1365-2249.1999.01026.x
10. Gerl V, Hostmann B, Johnen C, *et al.* The intracellular 52-kd Ro/SSA autoantigen in keratinocytes is up-regulated by tumor necrosis factor  $\alpha$  via tumor necrosis factor receptor I. *Arthritis & Rheumatism* 2005; 52(2): 531–538. doi: 10.1002/art.20851
11. Furukawa F, Ikai K, Matsuyoshi N, *et al.* Relationship between heat shock protein induction and the binding of antibodies to the extractable nuclear antigens on cultured human keratinocytes. *Journal of Investigative Dermatology* 1993; 101(2): 191–195. doi: 10.1111/1523-1747.ep12363785
12. Mikita N, Ikeda T, Ishiguro M, *et al.* Recent advances in cytokines in cutaneous and systemic lupus erythematosus. *The Journal of Dermatology* 2011; 38(9): 839–349. doi: 10.1111/j.1346-8138.2011.01237.x.
13. Méndez-Flores S, Hernández-Molina G, Azamar-Llamas D, *et al.* Inflammatory chemokine profiles and their correlations with effector CD4 T cell and

- regulatory cell subpopulations in cutaneous lupus erythematosus. *Cytokine* 2019; 119: 95–112. doi: 10.1016/j.cyto.2019.03.010
14. Furukawa F, Kashihara-Sawami M, Lyons MB, *et al.* Binding of antibodies to the extractable nuclear antigens SS-A/Ro and SS-B/La is induced on the surface of human keratinocytes by ultraviolet light (UVL): Implications for the pathogenesis of photosensitive cutaneous lupus. *Journal of Investigative Dermatology* 1990; 94(1): 77–85. doi: 10.1111/1523-1747.ep12873930
  15. Elman SA, Joyce C, Braudis K, *et al.* Creation and validation of classification criteria for discoid lupus erythematosus. *JAMA Dermatology* 2020; 156(8): 901–906. doi: 10.1001/jamadermatol.2020.1698
  16. Elman SA, Joyce C, Nyberg F, *et al.* Development of classification criteria for discoid lupus erythematosus: Results of a Delphi exercise. *Journal of the American Academy of Dermatology* 2017; 77(2): 261–267. doi: 10.1016/j.jaad.2017.02.030
  17. Furukawa F, Kanazawa N. Autoimmunity versus autoinflammation: From the 2nd JSID-Asia-Oceania-Forum, Wakayama, Japan, 5th December, 2010. *Journal of Dermatological Science* 2011; 63(2): 132–137. doi:10.1016/j.jdermsci.2011.05.001
  18. Wenzel J. Cutaneous lupus erythematosus: New insights into pathogenesis and therapeutic strategies. *Nature Reviews Rheumatology* 2019; 15: 519–532. doi: 10.1038/s41584-019-0272-0
  19. Sim JH, Ambler WG, Sollohub IF, *et al.* Immune cell-stromal circuitry in lupus photosensitivity. *Journal of Immunology* 2021; 206(2): 302–309. doi: 10.4049/jimmunol.2000905
  20. Kanazawa N, Furukawa F. Autoinflammatory syndromes with a dermatological perspective. *The Journal of Dermatology* 2007; 34(9): 601–618. doi: 10.1111/j.1346-8138.2007.00342.x
  21. Arima K, Kinoshita A, Mishima H, *et al.* Proteasome assembly defect due to a proteasome subunit beta type 8 (PSMB8) mutation causes the autoinflammatory disorder, Nakajo-Nishimura syndrome. *Proceedings of the National Academy of Science of the United States of America* 2011; 108(36): 14914–14919. doi: 10.1073/pnas.1106015108
  22. Inaba Y, Kanazawa N, Kunimoto K, *et al.* Antinuclear antibodies in Nakajo-Nishimura syndrome. A bridge with research on refractory autoimmune diseases. *Trends in Immunotherapy* 2018; 2(1): 1–2. doi: 10.24294/ti.v2.i3.1078
  23. Furukawa F. Hydroxychloroquine in lupus erythematosus, a new horizon of the old drug. *Trends in Immunotherapy* 2017; 1: 99–100. doi: 10.24294/ti.v1.i3.127
  24. Barton GM, Kagan JC. A cell biological view of Toll-like receptor function: regulation through compartmentalization. *Nature Reviews, Immunology* 2009; 9(8): 535–542. doi: 10.1038/nri2587
  25. Yamada M, Usami M, Otani K, *et al.* Nationwide product registry for hydroxychloroquine in Japanese patients with cutaneous and systemic lupus erythematosus (in Japanese). *Therapeutic Research* 2020; 41(4): 297–319.
  26. Sharma AN, Mesinkovska NA, Paravar T. Characterizing the adverse dermatologic effects of hydroxychloroquine: A systematic review. *Journal of the American Academy Dermatology* 2020; 83(2): 563–578. doi: 10.1016/j.jaad.2020.04.024.
  27. Matsuda T, Ly NTM, Kambe N, *et al.* Early cutaneous eruptions after oral hydroxychloroquine in a lupus erythematosus patient: A case report and review of the published work. *The Journal of Dermatology* 2018; 45(3): 344–348. doi: 10.1111/1346-8138.14156.
  28. Hirakawa Y, Okuno A, Kimura D, *et al.* Hydroxychloroquine enhanced urticarial reaction in a patient with discoid lupus erythematosus. *Trends in Immunotherapy* 2017; 1: 121–123. doi: 10.24294/ti.v1.i3.125
  29. Petri M, Elkhalfi M, Li J, *et al.* Hydroxychloroquine blood levels predict hydroxychloroquine retinopathy. *Arthritis & Rheumatology* 2020; 72(3): 448–453. doi: 10.1002/art.41121
  30. Yokogawa N, Ohno-Tanaka A, Hashiguchi M, *et al.* Early onset hydroxychloroquine retinopathy and a possible relationship with blood levels: Comment on the article by Petri *et al.* *Arthritis & Rheumatology* 2020; 73(2): 358–359. doi: 10.1002/art.41497.
  31. Lenfant T, Salah S, Leroux G, *et al.* Risk factors for hydroxychloroquine retinopathy in systemic lupus erythematosus: A case-control study with hydroxychloroquine blood-level analysis. *Rheumatology (Oxford)* 2020; 59(12): 3807–3816. doi: 10.1093/rheumatology/keaa157.
  32. Ozawa H, Ueno S, Ohno-Tanaka A. Ocular findings in Japanese patients with hydroxychloroquine retinopathy developing within 3 years of treatment. *Japanese Journal of Ophthalmology* 2021; 65: 472–481. doi: 10.1007/s10384-021-00841-9
  33. Yokogawa N. Launch of hydroxychloroquine-history in Japan (in Japanese). *Visual Dermatology* 2017; 16: 106–110.
  34. Ikeda T. Clinical characteristics of hydroxychloroquine effective skin lesion (in Japanese). *Visual Dermatology* 2017; 16: 112–117.
  35. Fernandez AP. Updated recommendations on the use of hydroxychloroquine in dermatologic practice. *Journal of the American Academy of Dermatology* 2017; 76(6): 1176–1182. doi: 10.1016/j.jaad.2017.01.012
  36. Yoshida M, Minowa K, Amano H, *et al.* Combining maintenance therapy with hydroxychloroquine increases LLDAS achievement rates in individuals with stable systemic lupus erythematosus. *Lupus* 2021. doi: 10.1177/09612033211014272
  37. Yan D, Borucki R, Sontheimer RD, *et al.* Candidate drug replacements for quinacrine in cutaneous lupus erythematosus. *Lupus Science & Medicine* 2020; 7(1). doi: 10.1136/lupus-2020-000430
  38. Matyskiela ME, Zhang W, Man HW, *et al.* A cereblon modulator (CC-220) with improved degradation of Ikaros and Aiolos. *Journal of Medicinal Chemistry* 2018; 61(2): 535–542. doi: 10.1021/acs.jme

dchem.6b01921

39. Chen C, Pan K, Wu B, *et al.* Safety of hydroxychloroquine in COVID-19 and other diseases: A systematic review and meta-analysis of 53 random-

ized trials. *European Journal of Clinical Pharmacology* 2021; 77: 13–24. doi: 10.1007/s00228-020-02962-5