

## CASE REPORT

# Summary of COVID-19 vaccine-related erythema multiforme at Kindai University Hospital, Japan

Keiko Watanabe, Chisa Nakashima\*, Ayako Matsuo, Maiko Kato, Shigeto Yanagihara, Naoki Oiso, Atsushi Otsuka

Department of Dermatology, Faculty of Medicine, Kindai University Hospital, 377-2 Ohno-higashi, Osaka-Sayama, Osaka 589-8511, Japan. E-mail: chisa313@med.kindai.ac.jp

---

## ABSTRACT

The recently extended use of mRNA vaccines due to the COVID-19 pandemic has allowed the description of multiple cutaneous adverse events including local injection site reactions, urticaria, and morbilliform eruptions. COVID-19 vaccine-related cutaneous reaction patterns can be divided into type I hypersensitivity reactions, type IV hypersensitivity reactions, autoimmune-related, and functional angiopathies based on pathogenesis. Erythema multiforme (EM), a type IV hypersensitivity reaction, has also been reported from several centers. We experienced the remarkable improvement of COVID-19 vaccine-related EM with systemic administration of prednisolone and summarized six cases experienced in our department.

**Keywords:** COVID-19; Erythema Multiforme Vaccination

---

## ARTICLE INFO

---

Received 31 August 2022  
Accepted 6 September 2022  
Available online 14 December 2022

## COPYRIGHT

---

Copyright © 2022 Keiko Watanabe, *et al.*  
EnPress Publisher LLC. This work is licensed under the Creative Commons Attribution-NonCommercial 4.0 International License (CC BY-NC 4.0).  
<https://creativecommons.org/licenses/by-nc/4.0/>

## 1. Introduction

Erythema multiforme (EM) is an immune-mediated skin disease that presents with cutaneous or mucosal lesions or both. EM can be induced by various factors including viral infections (simplex virus and mycoplasma are the most common causes) and drugs. EM is usually caused by delayed-type hypersensitivity (type IV allergy) reactions to infections or drugs. Typical histopathologic findings of EM include orthokeratosis, individual cell necrosis of keratinocytes within the epidermis, vacuolar degeneration of the basement membrane, and inflammatory cell infiltration of the upper dermis.

The recently extended use of mRNA vaccines BNT162b2 (Pfizer-BioNTech) and mRNA-1273 (Moderna) due to the COVID-19 pandemic has allowed the description of multiple cutaneous adverse events including local injection site reactions, urticaria, and morbilliform eruptions. COVID-19 vaccine-related cutaneous reaction patterns can be divided into type I hypersensitivity reactions, type IV hypersensitivity reactions, autoimmune-related, and functional angiopathies based on pathogenesis<sup>[1]</sup>. EM has also been reported from several centers. Since we experienced six cases of EM after COVID-19 vaccination from June to August 2021, we report the case report and our summary.

## 2. Case report

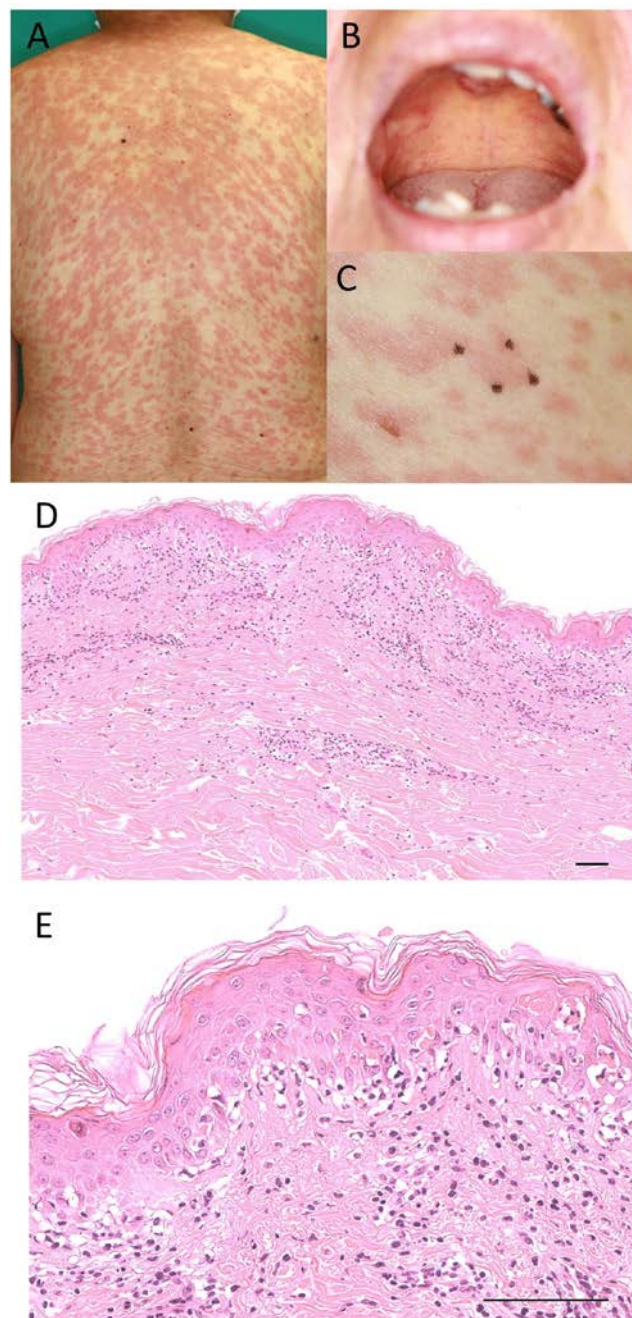
A 77-year-old female came to our department because of her erythema. She had a fever on the 5th day after the second dose of the

COVID-19 vaccine, and erythema starting from the face was observed on the 7th day, and erythema appeared on the trunk with fever release. Clinical manifestation revealed erythema with infiltration on her body (**Figure 1A**). There were no obvious bullae or purpura, and no pruritus was observed. Two erosions were found in the oral cavity (**Figure 1B**). Laboratory investigation revealed no abnormalities except for a mild deviation of liver enzymes. Serological measurements of cytomegalovirus, herpes simplex virus, and EB virus antibody titers all showed an existing infection pattern. There was no history of oral medication. Histological findings revealed interface dermatitis with individual cell necrosis in the epidermis and inflammatory cell infiltration in the shallow dermis (**Figures 1C, D, and E**). The patient was admitted to the hospital and started on prednisolone (PSL) at 60 mg/day (1 mg/kg/day). Erythema showed a tendency to improve after the start of PSL administration. After the completion of steroid administration, no flare-up of the skin rash was observed. The patient was referred to the Department of Respiratory Medicine at our hospital because a thymoma was noted on the CT scan of the chest taken at the time of admission. After completion of steroid administration and improvement of her general condition, she was scheduled for surgery.

### 3. Discussion

In this case, we demonstrate the remarkable improvement of EM with systemic administration of PSL. According to the registry-based study of 414 cases, three cases of EM were reported, which were observed the first time after vaccination with the mRNA-1273 (Moderna)<sup>[2]</sup>. Another group reported 3 cases were EM of the 38 patients who had skin reactions after COVID-19 vaccination and all 3 cases were reported 7–14 days after the first vaccination<sup>[3]</sup>.

Then, we summarized six cases experienced in our department. It can be summarized as two males and four females, ranging in age from 19 to 77 years (average 54 years). The number of vaccine inoculations was the first in five cases and the second in one case, and the time from vaccination to



**Figure 1.** Case presentation and summary of COVID-19 vaccine related-EM. Clinical pictures of the back (**A**) and the oral cavity (**B**). (**C**) A skin biopsy of the dorsal erythema was performed. The skin biopsy site is indicated by an allow-head. Histology of H & E staining, (**D**) (**E**) Scale bar is 100  $\mu$ m.

disease onset ranged from 4 to 20 days, with the exception of one case, in which disease onset occurred within about one week, consistent with previous reports. Systemic steroid administration was required in three cases. Two patients received immune checkpoint inhibitors because of their primary diseases (**Table 1**).

**Table 1**

Age	Sex	Histology	Vaccine	Timepoint (day)	Dose	Concomitant disease	Treatment
68	F	Interface dermatitis with vacuolar change. Eosinophil infiltration	Unknown	4	1		Application of PSL ointment
67	M	Interface dermatitis	BNT162b2 (Pfizer-BioNTech)	7	1	Diabetes, hypertension	Systemic PSL (maximum 50 mg/day)
77	F	Interface dermatitis	Unknown	7	2	Thymoma	Systemic PSL (maximum 60 mg/day)
47	M	Interface dermatitis	mRNA-1273 (Moderna)	8	1	Hyperlipidemia	Application of PSL ointment
19	F	N.D.	Unknown	6	1	None	Application of PSL ointment
46	F	Interface dermatitis, vacuolar with partial spongiosis	mRNA-1273 (Moderna)	20	1	Lung cancer	Systemic PSL (maximum 60 mg/day)

EM is also known to be induced by various causes, including viral infections and drugs. Actually, in one of our cases, EM was thought to have developed after COVID-19 vaccination, but serological investigation for the virus revealed that cytomegalovirus infection was suspicious later. It is important to note that the possibility of drug eruptions or viral infections must be ruled out. With the increase in the number of COVID-19 vaccinations and the start of additional vaccinations, the number of cases presenting with various types of skin rash, including EM, is expected to increase. Further accumulation of cases is expected in the future.

### Author contributions

K.W. and C.N. wrote the manuscript, and all the authors critically revised it.

### Consent

Written informed consent was obtained for publication of this case report and any accompanying images.

### Conflict of interest

The authors declare that there is no conflict of interest with respect to the research, authorship,

and/or publication of this article.

### Acknowledgements

This work was supported in part by Grants-in-Aid for Scientific Research from the Ministry of Education, Culture, Sports, Science and Technology and the Ministry of Health, Labour and Welfare of Japan (to A. Otsuka).

### References

- Gambichler T, Boms S, Susok L, *et al.* Cutaneous findings following COVID-19 vaccination: Review of world literature and own experience. *Journal of the European Academy of Dermatology and Venereology* 2022; 36(2): 172–180. doi: 10.1111/jdv.17744.
- McMahon DE, Amerson E, Rosenbach M, *et al.* Cutaneous reactions reported after Moderna and Pfizer COVID-19 vaccination: A registry-based study of 414 cases. *Journal of the American Academy of Dermatology* 2021; 85(1): 46–55. doi: 10.1016/j.jaad.2021.03.092.
- Grieco T, Maddalena P, Sernicola A, *et al.* Cutaneous adverse reactions after COVID-19 vaccines in a cohort of 2740 Italian subjects: An observational study. *Dermatologic Therapy* 2021; 34(6): e15153. doi: 10.1111/dth.15153.