

ORIGINAL ARTICLE

Combination of Alvarado score and ultrasound findings in diagnosis of acute appendicitis in children

Tamer Fakhry^{1*}, Mohamed Shawky²

¹ Pediatric Surgery Unit, General Surgery Department, Menoufia University Hospitals, Shebin el Kom, Al Menoufia, Egypt

² Radiology Department, Menoufia University Hospitals, Shebin el Kom, Al Menoufia, Egypt

ABSTRACT

Appendicitis is the most common cause of emergency abdominal surgeries in children. Ultrasound (US) has been proven to be a helpful imaging modality in patient evaluation, especially in children suspected of appendicitis. The Alvarado score is a 10-point scoring system for the diagnosis of appendicitis based on clinical data and differential leukocyte count. The aim of the present study was to evaluate a combination of clinical scoring (Alvarado score) and US findings for accurate diagnosis of appendicitis in children. The study was done in Menoufia University Hospitals from March 2011 to January 2013. 322 children with abdominal pain clinically suspected of having appendicitis were included in the study and clinically assessed to calculate the Alvarado score. Patients were referred to the radiology department for abdominal US. Among the 153 of the 322 patients who were operated on, 149 patients were diagnosed pre-operatively with acute appendicitis and 4 girls were diagnosed with complex ovarian cysts. Of the 149 patients diagnosed with appendicitis, the percentage of appendicitis was 93% (139/149) and 10 (7%) patients had normal appendix. The prevalence of appendicitis among the patients of the study was 43% (139/322). In conclusion, a combination of Alvarado scores and abdominal US is a good approach for the diagnosis of appendicitis in children to reduce the number of laparotomies for normal appendix. In the case of normal appendix or non-visualization of the appendix via abdominal US without a high Alvarado score, appendicitis can be safely ruled out. If it is proven as an inflamed appendix on US or a high Alvarado score, patient should be subjected for appendectomy without delay.

Keywords: Alvarado; appendicitis; ultrasound

ARTICLE INFO

Received: December 22, 2017

Accepted: January 27, 2018

Available online: June 8, 2018

*CORRESPONDING AUTHOR

Tamer Fakhry, Masnaa St, Shebin el Kom, Menoufia, Egypt,
tamer_fakhry26@yahoo.com

CITATION

Fakhry T, Shawky M. Combination of Alvarado score and ultrasound findings in diagnosis of acute appendicitis in children. J Pediatr Dis 2018; 1: 100. doi: 10.24294/jpedd.v1i1.100

COPYRIGHT

Copyright © 2018 by author(s) and EnPress Publisher LLC. This work is licensed under the Creative Commons Attribution-NonCommercial 4.0 International License (CC BY-NC 4.0). <http://creativecommons.org/licenses/by-nc/4.0/>

Introduction

Acute appendicitis in children and adolescents is the most common cause of emergency abdominal surgeries^[1,2]. Symptoms of appendicitis overlap with a number of other conditions, thus making diagnosis a challenge especially at an early stage of presentation^[3]. The challenge is that it is difficult to obtain a clear history in children as not all patients present classical symptoms and many disorders of the gastrointestinal tract mimic acute appendicitis^[4]. Acute appendicitis remains a clinical diagnosis but when the diagnosis of acute appendicitis is difficult, abdominal ultrasound (US) has been proven to be a helpful imaging modality in patient evaluation, especially in children suspected of appendicitis^[5,6].

There are several methods to assist the diagnosis of acute appendicitis other than US: laparoscopy, scoring systems such as the Alvarado score, computed tomography (CT) and magnetic resonance imaging (MRI)^[7-10]. According to literatures, sensitivity and specificity of CT in diagnosing appendicitis is higher than US^[11,12]. However, due to long-term risk of ionizing radiation, CT should not be the preferred imaging method, especially in children. Moreover, the high cost limits the use of CT scan as a routine imaging modalities for the diagnosis of acute appendicitis^[13]. MRI is also associated with disadvantages

including cost, time and potential need for sedation to obtain an accurate result^[14].

Graded compression US is the least expensive and least invasive method that has been reported to have an accuracy of 70%–95%^[15]. Strategies to increase the utility of US as a diagnostic tool for appendicitis are desirable to reduce radiation exposure and to decrease the cost, but US has its challenges as well. Appendix visualization rates vary and US exhibits significant user dependency^[16].

The Alvarado score is a 10-point scoring system for the diagnosis of appendicitis based on clinical signs, symptoms and differential leukocyte count^[17]. The Alvarado score was originally designed more than two decades ago as a diagnostic score. However, its performance and appropriateness for routine clinical use is still unclear^[18]. Therefore, the purpose of this study was to evaluate the use of US findings combined with Alvarado scores in diagnosing children with suspected appendicitis.

Materials and methods

This was a prospective study done in Menoufia University Hospitals from March 2011 to January 2013. 322 children (below 18 years old) with acute abdominal pain (acute onset < 3 days) and clinically suspected of having acute appendicitis were included in the study. They were clinically assessed for Alvarado score calculations, and their blood samples were taken for routine laboratory investigations including complete blood count (CBC), liver and kidney profiles. Patients were then referred to the department of radiology for abdominal US. The subject group (N = 322) included 149 boys and 173 girls with a mean age of 11.3 years (age range: 4–16 years). Prior to the inclusion of the patients in the study, an ethical clearance was sought from the competent authority of Menoufia University Hospitals. Written informed consent was obtained from the patients' guardians for publication of this report and any accompanying images.

Alvarado scores (**Table 1**) were calculated and patients were classified into three groups according to the score: (i) low Alvarado scores (Alvarado score ≤ 4); (ii) moderate Alvarado scores (Alvarado scores 5 and 6); (iii) high Alvarado scores (Alvarado score ≥ 7).

After the calculation of their Alvarado scores, patients were referred to a radiologist for abdominal US. The entire abdomen was examined with a 4 MHz curved-array transducer and the right lower quadrant of the abdomen with a 10 MHz linear-array

transducer. All abdominal organs were examined and graded compression of the right lower quadrant of the abdomen was used. The radiologist had no information on patients' Alvarado scores. Patients were classified according to the results of the abdominal US in four groups: group 1 with normal visualized appendix (diameter < 6 mm); group 2 with appendix not visualized but without secondary signs of appendicitis (i.e., local fluid collections or local dilatation of the bowel without peristalsis (**Figure 1**), indicating focal peritonitis or increased echogenicity of the surrounding mesenteric fat); group 3 with appendix not visualized but one or more of the secondary signs of appendicitis were present; and group 4 having appendicitis with visualization of an inflamed appendix (**Figure 2**) or perforated appendicitis (**Figure 3**). Criteria for the US diagnosis of inflamed appendix included identification of the appendix as a fluid-filled, non-compressible, blind-ended tubular structure with diameter ≥ 6 mm (**Figure 4**) and hyperemia of the wall of the appendix (**Figure 5**). US findings in perforated appendicitis were target signs (**Figure 6**) and tubular structures with inhomogeneous structures and/or missing layers in the wall. Other diagnoses found during US were also recorded.

Table 1. Calculation of Alvarado scores

Symptoms	Score
Migratory right iliac fossa pain	1
Nausea/vomiting	1
Anorexia	1
Signs	Score
Tenderness in the right iliac fossa	2
Rebound tenderness in the right iliac fossa	1
Elevated temperature	1
Laboratory findings	Score
Leukocytosis	2
Neutrophils shifted to the left	1
Total	10

After clinical examinations, calculation of Alvarado scores, laboratory investigations and abdominal US, patients were either discharged (Alvarado score ≤ 4 in US groups 1 and 2) with follow-up appointments in the outpatient clinic after one week and instruction to return if pain recurs; subjected to appendectomy (high Alvarado score ≥ 7); or admitted for 24-hour observation (patients with moderate Alvarado scores of 5 and 6, or patients with low Alvarado scores from US groups 3 and 4), after which they were re-evaluated. All patients were followed-up weekly for two months.

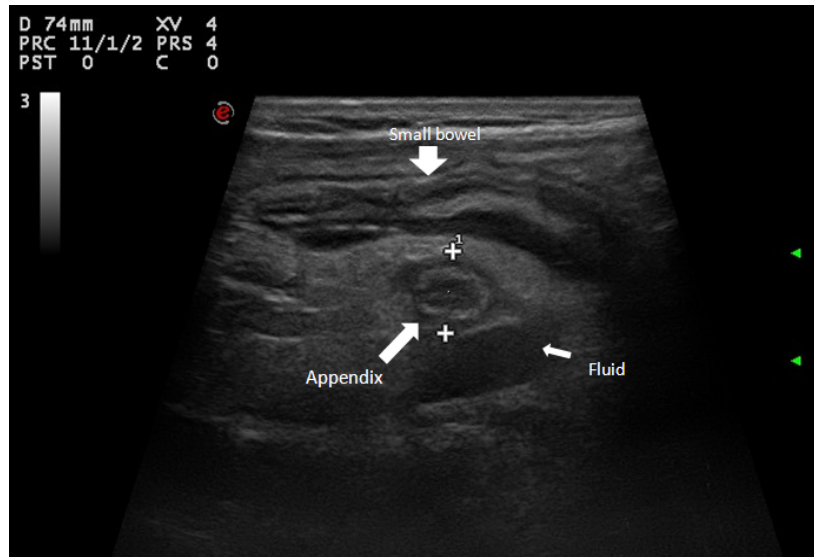


Figure 1. Acute appendicitis: thickened edematous bowel, small bowel loop in vicinity and surrounding fluid collection

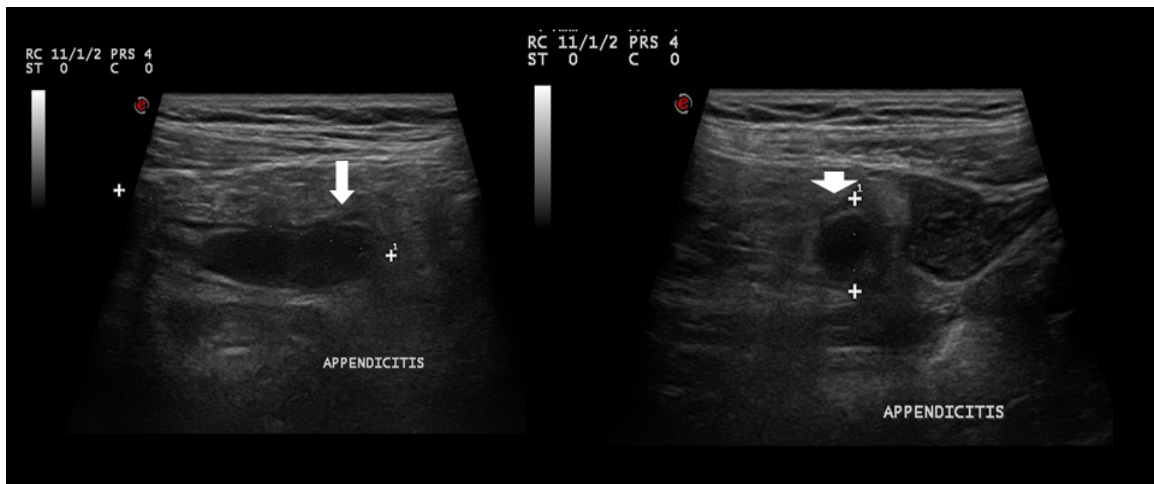


Figure 2. Acute appendicitis: distended appendix (arrow)

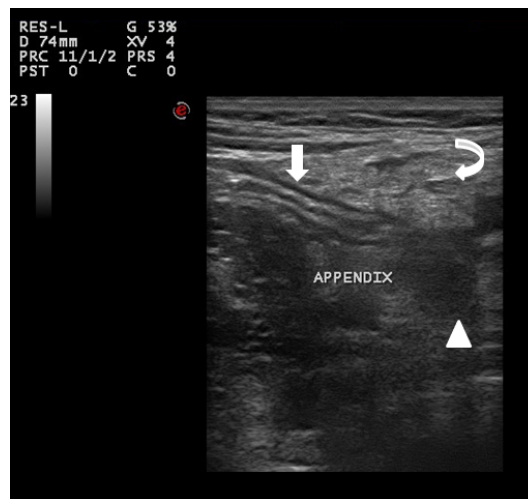


Figure 3. Perforated acute appendicitis: inflamed appendix (arrow) with hypoechoic fluid collection at perforated tip (arrow head) and inflamed omentum (curved arrow)

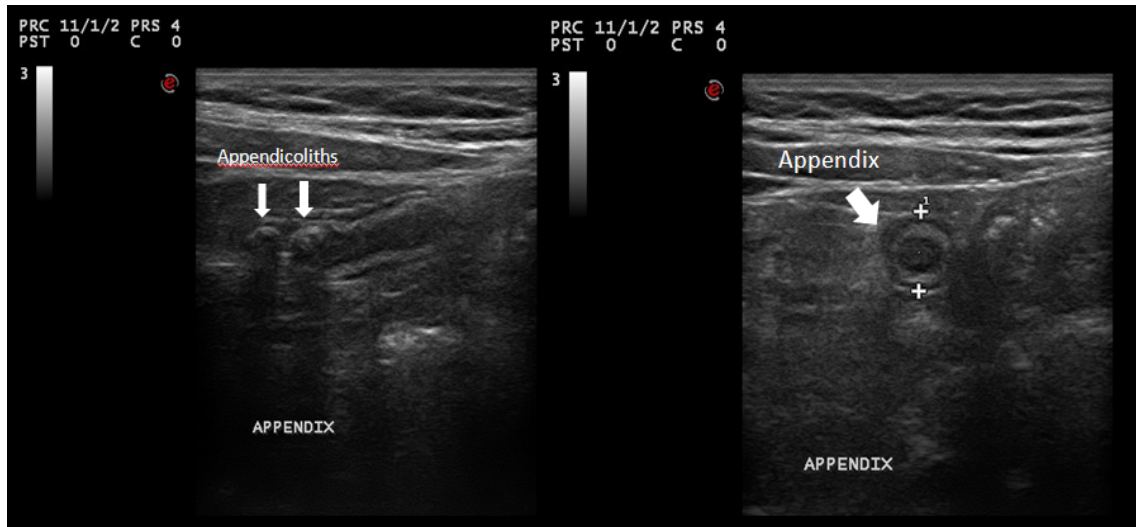


Figure 4. Acute appendicitis with appendicoliths

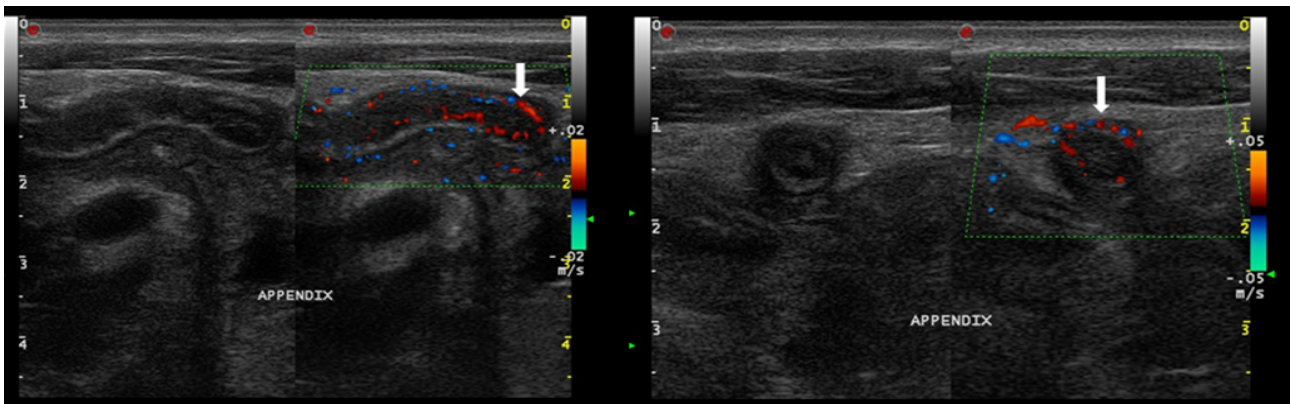


Figure 5. Acute appendicitis: Doppler imaging showing increased vascularity of the walls in axial and longitudinal views

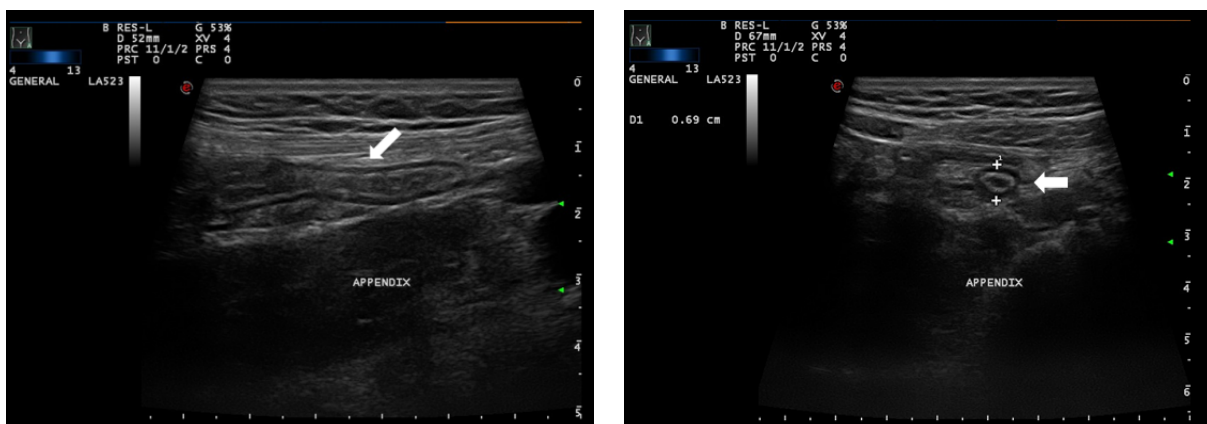


Figure 6. Acute appendicitis: target sign in axial scan and blind-ended structure in longitudinal scan (arrow)

We considered the results as negative for appendicitis when patients' complaints were either resolved upon re-evaluation in the outpatient clinic, patients did not go to another hospital during follow-

up, patients had a successful response to conservative treatment of an alternative diagnosis, or when patients were already operated on and the presence of normal appendix was proven as operative finding

and/or pathological. We excluded patients who could not come to the outpatient clinic for follow-up and re-evaluation.

Ethics Statement

Prior to the inclusion of the patients in the study, an ethical clearance was sought from the competent authority of Menoufia University Hospitals. Written informed consent was obtained from patients' guardians for publication of this research and any accompanying images.

Results

The study included 322 patients with suspected acute appendicitis based on their Alvarado scores. Patients were classified into three groups (as shown in **Table 2**):

Low Alvarado scores (Alvarado score ≤ 4): 153 children were sub-classified according to US findings with 47 patients from group 1, group 2 with 102 patients, and group 3 that included 4 patients. All patients with low Alvarado scores from US groups 1 and 2 were given expectant treatments or conservative treatments, and discharged with appointments in the outpatient clinic after one week. Patients were informed to return if pain recurs at any time. All of them came for the follow-up appointment with no complaints. In the US

group 3, 2 girls showed complex right ovarian cysts with right iliac fossa collection and were operated for that diagnosis. The remaining 2 patients were admitted for observation: 1 patient was operated (proven intraoperatively to have acute appendicitis) due to the persistence of symptoms and increased leukocyte count after 24 h, while the other patient was discharged after 24 h observation and was free from pain on conservative treatment.

Moderate Alvarado scores (Alvarado scores 5 and 6): 32 patients, with no patient from group 1 and 21 patients from group 2 – of which 2 girls were diagnosed with complex ovarian cysts on US and were operated on. The remaining 19 patients were admitted for follow-up and re-assessed after 24 h. 17 patients were relieved of pain and discharged with a follow-up appointment after one week. 2 patients were re-assessed and their Alvarado scores became more than 7, and were therefore suggested for appendectomy. Operative findings and pathology proved acute appendicitis in 1 patient and the other had normal appendix. 11 patients from groups 3 and 4 were admitted for 24 h follow-up and re-assessed within 24 h. 2 were relieved of pain and discharged with a follow-up appointment after one week while 9 patients had re-assessment scores of more than 7 and were suggested for appendectomy. Operative findings and pathology proved acute appendicitis in 5 patients and normal appendix in 4.

Table 2. Alvarado scores combined with US findings for decision and final diagnosis

US group	No. of patients, N (%)	Alvarado score			Decision and final diagnosis
		Group 1 (Low: ≤ 4)	Group 2 (Moderate: 5 and 6)	Group 3 (High: ≥ 7)	
US Group 1	47/322 (14.6%)	47 conservative treatments. None were diagnosed with appendicitis.	0	0	No operation, conservative treatment and follow-up
US Group 2	133/322 (41.3%)	102 for conservative treatments (-ve for appendicitis)	21 (4 were operated with 1 +ve and 1 -ve for appendicitis, and 2 for ovarian cysts; remaining patients managed conservatively)	10 patients (all of them were operated with 3 +ve and 7 -ve for appendicitis)	2 patients were operated for ovarian cysts, 12 patients were operated for appendicitis, 8 proven to have normal appendix, remaining patients for conservative treatment
US Groups 3 & 4	142/322 (44.1%)	4 (1 were operated, +ve for appendicitis; 2 for ovarian cysts; and 1 for conservative treatment)	11 (9 were operated with 5 +ve and 4 -ve for appendicitis; 2 for conservative treatment)	127 (all were operated with 126 +ve and 1 -ve for appendicitis)	2 patients were operated for ovarian cysts, 137 were operated diagnosed as appendicitis, 5 had normal appendix
TOTAL	322	153	32	137	

High Alvarado scores (Alvarado score ≥ 7): 137 patients, with no patient from group 1, 10 patients from group 2, and 127 patients from groups 3 and 4. All patients with high Alvarado scores were operated for appendectomy. 7 patients in group 2 had normal appendix and 1 patient in groups 3 and 4 each proved to have normal appendix in the operative finding.

153 patients were operated on. 149 patients were clinically diagnosed pre-operatively with acute appendicitis and 4 girls were diagnosed with complex ovarian cysts. Of the 149 patients diagnosed with acute appendicitis, the percentage of appendicitis confirmed upon surgery and/or pathology was 91.2% (136/149) while 13 (8.8%) patients had normal appendix. The prevalence of appendicitis among patients of the study was 42.2% (136/322). The diagnostic accuracy of US for clinical diagnosis of acute appendicitis was as follows (as shown in **Table 3**): sensitivity, 97.0% (132/136); specificity, 94.4% (176/186); positive predictive value, 92.9% (132/142); negative predictive value, 97.0% (176/180); and accuracy, 95.6% (308/322). Diagnostic accuracy of Alvarado scores for the clinical diagnosis of acute appendicitis was as follows(as shown in **Table 4**): sensitivity, 92.8 % (129/140); specificity, 95.6% (174/182); positive predictive value, 94.1% (129/137); negative predictive value, 94.0% (174/185); and accuracy, 94.2% (303/322). When patients' Alvarado scores were combined with US findings, specifically low grade Alvarado scores with US groups 1 and 2, results showed no false negative cases and diagnosis was accurate by 100%. The combination of high Alvarado scores and US groups 3 and 4 showed only one false positive case with an accuracy of 99.2% (126/127).

Discussion

Acute appendicitis is one of the most common surgical emergencies within the pediatric age group^[19]. It is now more acceptable to perform appendectomy on normal appendix with the availability of well-trained surgeons and nurses in hospitals

Table 3. Diagnostic accuracy of US for the clinical diagnosis of acute appendicitis

	Confirmed appendicitis	No appendicitis	Total
US findings +ve Groups 3 and 4	132	10	142
US findings -ve Groups 1 and 2	4	176	180
TOTAL	136	186	322

Table 4. Diagnostic accuracy of Alvarado scores for the clinical diagnosis of acute appendicitis

	Confirmed appendicitis	No appendicitis	Total
Low and intermediate Alvarado scores	129	8	137
High Alvarado scores	11	174	185
TOTAL	140	182	322

and with the evolution of imaging tools such as the US, CT scan and MRI.

Diagnosis of acute appendicitis remains a clinical skill. However, both US and CT have been reported to improve accuracy in the diagnosis of acute appendicitis^[20]. CT scan rates for the diagnosis of acute appendicitis have been increasing nationally^[21, 22]. Although CT is reported to have a higher sensitivity than US, ongoing concerns have been raised regarding radiation exposure and increased costs associated with CT scans^[12]. Projections estimated that a solid cancer will result at a rate of 25.8 to 33.9 cases per 10,000 abdominal CT scans in girls and, 13.1 to 14.8 cases per 10,000 abdominal CT scans in boys^[23]. Furthermore, high costs and the need for sedation would limit the use of CT and MRI for diagnosing appendicitis in children. Strategies to increase the use of US as a diagnostic imaging tool for acute appendicitis are desirable to reduce radiation exposure and decrease costs. However, US has its own challenges as well.

Appendix visualization rates vary and US has the disadvantage of user dependency^[15]. In a 2010 systematic review, the authors reviewed studies published during the period between January 2000 to March 2007 and found that the sensitivity of US for the diagnosis of acute appendicitis in children varied between 78% and 100%, and the specificity from 88% to 98%^[24]. Recent studies have reported sensitivity of 91% to 99% and specificity of 97% to 98%^[15]. In this study, the diagnostic accuracy of US for clinical diagnosis of acute appendicitis was as follows: sensitivity, 97.0% (132/136); specificity, 94.4% (176/186); positive predictive value, 92.9% (132/142); negative predictive value, 97.0% (176/180); and accuracy, 95.6% (308/322).

In diagnosing acute appendicitis, surgeons balanced the risk of removing a normal appendix against the risk of perforation. The Alvarado score is a widely published 10-point clinical scoring system, a convenient tool for aiding the diagnosis of appendicitis and decrease the number of

appendectomies for normal appendix^[25]. It is known by the mnemonic ‘MANTRELS’ and is scored as follows: right iliac fossa pain (1 point), anorexia (1 point), nausea or vomiting (1 point), right lower quadrant tenderness (2 point), rebound tenderness (1 point), elevated temperature $\geq 37.3^{\circ}\text{C}$ (1 point), leukocytes $\geq 11\,000$ (2 points), and differential white blood cell count with 75% neutrophils (1 point)^[26,27]. Alvarado scores have been previously shown to be relatively sensitive and specific in adults with lower right quadrant pain. As a diagnostic tool for the diagnosis of acute appendicitis in the pediatric age group, a cut-off point of 5 points appeared to be fairly sensitive (99% in the systematic review by Ohle *et al.*^[18], and 89.7% in the study by Mandeville *et al.*^[28]). Scores of 7–10 have shown sensitivities ranging from 72% to 92% and specificities ranging from 64.4% to 82.0%. In this study, the diagnostic accuracy of Alvarado scores with a cut-off point of 6 for the clinical diagnosis of acute appendicitis was as follows: sensitivity, 92.8% (129/140); specificity, 95.6% (174/182); positive predictive value, 94.1% (129/137); negative predictive value, 94.0% (174/185); and accuracy, 94.2% (303/322).

We used Alvarado clinical scores combined with US findings to identify children with a high or low probability of appendicitis. In the present study, combining low grade Alvarado scores with US groups 1 and 2 (negative US findings) showed no false negative cases and diagnosis was accurate by 100%. Moreover, combining high Alvarado scores with US groups 3 and 4 (positive US findings), resulted in only one false positive case with an accuracy of 99.2% (126/127).

The limitation of this study was the lack of pathological diagnosis in patients for whom no appendectomy was performed. We considered the results as true negatives when patients come to the outpatient clinic with resolved complaints on re-evaluation or if patients had a successful response to conservative treatment of an alternative diagnosis.

Conclusion

In conclusion, acute appendicitis was ruled out in patients with low Alvarado scores and negative US findings (US groups 1 and 2). Acute appendicitis was confirmed in patients with high Alvarado scores and positive US findings (groups 3 and 4) and appendectomy should be done without delay. Patients with low Alvarado scores and positive US findings or moderate and high Alvarado scores with negative US findings should be observed for 24 h and appendectomy is only done when manifestations persist. A combination of Alvarado scores and

abdominal US is a good approach for the diagnosis of acute appendicitis in children, reducing the number of laparotomies for normal appendix.

Conflict of interest

The authors declared no potential conflict of interest with respect to the research, authorship, and/or publication of this article.

References

1. Treutner KH, Schumpelick V. Epidemiologie der appendicitis (German) [Epidemiology of appendicitis]. *Chirurg* 1997; 68(1): 1–5. doi: 10.1007/s001040050142.
2. Berlin SC, Sivit CJ, Stringer DA. Large bowel. In: Stringer DA, Babyn PS, (editors). *Pediatric gastrointestinal imaging and intervention*. 2nd ed. London: B.C. Decker Inc.; 2000. p. 475–549.
3. Bundy DG, Byerley JS, Liles EA, Perrin EM, Katznelson J, *et al.* Does this child have appendicitis? *J Am Med Assoc* 2007; 298(4): 438–451. doi: 10.1001/jama.298.4.438.
4. Wong KKY, Cheung TWY, Tam PKH. Diagnosing acute appendicitis: Are we overusing radiologic investigations? *J Pediatr Surg* 2008; 43(12): 2239–2241. doi: 10.1016/j.jpedsurg.2008.08.054.
5. Dilley A, Wesson D, Munden M, Hicks J, Brandt M, *et al.* The impact of ultrasound examinations on the management of children with suspected appendicitis: A 3-year analysis. *J Pediatr Surg* 2001; 36(2): 303–308. doi: 10.1053/jpsu.2001.20702.
6. Sivit CJ, Newman KD, Boenning DA, Nussbaum-Blask AR, Bulas DI, *et al.* Appendicitis: Usefulness of US in diagnosis in a pediatric population. *Radiology* 1992; 185(2): 549–552. doi: 10.1148/radiology.185.2.1410371.
7. Moberg AC, Ahlberg G, Leijonmarck CE, Montgomery A, Reiertsen O, *et al.* Diagnostic laparoscopy in 1043 patients with suspected acute appendicitis. *Eur J Surg* 1998; 164(11): 833–840. doi: 10.1080/110241598750005246.
8. Alvarado A. A practical score for the early diagnosis acute appendicitis. *Ann Emerg Med* 1986; 15(5): 557–564. doi: 10.1016/S0196-0644(86)80993-3.
9. Balthazar EJ, Megibow AJ, Siegel SE, Birnbaum BA. Appendicitis: Prospective evaluation with high-resolution CT. *Radiology* 1991; 180(1): 21–24. doi: 10.1148/radiology.180.1.2052696.
10. Incesu L, Coskun A, Selcuk MB, Akan H, Sozubir S, *et al.* Acute appendicitis: MR imaging and sonographic correlation. *Am J Roentgenol* 1997; 168(3): 669–674. doi: 10.2214/ajr.168.3.9057512.
11. Sivit CJ, Applegate KE, Stallion A, Dudgeon DL, Salvator A, *et al.* Imaging evaluation of suspected appendicitis in a pediatric population: Effectiveness

- of sonography versus CT. *Am J Roentgenol* 2000; 175(4): 977–980. doi: 10.2214/ajr.175.4.1750977.
12. Doria AS, Moineddin R, Kellenberger CJ, Epelman M, Beyene J, *et al.* US or CT for diagnosis of appendicitis in children and adults? A meta-analysis. *Radiology* 2006; 241(1): 83–94. doi: 10.1148/radiol.2411050913.
 13. Garcia Peña BM, Mandl KD, Kraus SJ, Fischer AC, Fleisher GR, *et al.* Ultrasonography and limited computed tomography in the diagnosis and management of appendicitis in children. *J Am Med Assoc* 1999; 282(11): 1041–1046. doi: 10.1001/jama.282.11.1041.
 14. Aspelund G, Fingeret A, Gross E, Kessler D, Keung C, *et al.* Ultrasonography/MRI versus CT for diagnosing appendicitis. *Pediatrics* 2014; 133(4): 586–593. doi: 10.1542/peds.2013-2128.
 15. Quigley AJ, Stafrace S. Ultrasound assessment of acute appendicitis in paediatric patients: Methodology and pictorial overview of findings seen. *Insights Imaging* 2013; 4(6): 741–751. doi: 10.1007/s13244-013-0275-3.
 16. Lee JH, Jeong YK, Park KB, Park JK, Jeong AK, *et al.* Operator-dependent techniques for graded compression sonography to detect the appendix and diagnose acute appendicitis. *Am J Roentgenol* 2005; 184(1): 91–97. doi: 10.2214/ajr.184.1.01840091.
 17. Winn RD, Laura S, Douglas C, Davidson P, Gani JS. Protocol-based approach to suspected appendicitis, incorporating the Alvarado score and outpatient antibiotics. *ANZ J Surg* 2004; 74(5): 324–329. doi: 10.1111/j.1445-1433.2004.02993.x.
 18. Ohle R, O'Reilly F, O'Brien KK, Fahey T, Dimitrov BD. The Alvarado score for predicting acute appendicitis: A systematic review. *BMC Med* 2011; 9: 139. doi: 10.1186/1741-7015-9-139.
 19. Abdus Salam A, Shahidul A, Quamruzzaman SM, Anisur Rahman M. Diagnosing acute appendicitis in children using Alvarado score. *AKMMC J* 2011; 2(2): 11–13.
 20. Nielsen JW, Boomer L, Kurtovic K, Lee E, Kupzyk K, *et al.* Reducing computed tomography scans for appendicitis by introduction of a standardized and validated ultrasonography report template. *J Pediatr Surg* 2015; 50(1): 144–148. doi: 10.1016/j.jpedsurg.2014.10.033.
 21. Bachur RG, Hennelly K, Callahan MJ, Chen C, Monuteaux MC. Diagnostic imaging and negative appendectomy rates in children: effects of age and gender. *Pediatrics* 2012; 129(5): 877–884. doi: 10.1542/peds.2011-3375.
 22. Tsze DS, Asnis LM, Merchant RC, Amanullah S, Linakis JG. Increasing computed tomography use for patients with appendicitis and discrepancies in pain management between adults and children: An analysis of the NHAMCS. *Ann Emerg Med* 2012; 59(5): 395–403. doi: 10.1016/j.annemergmed.2011.06.010.
 23. Parker L, Nazarian LN, Gingold EL, Palit CD, Hoey CL, *et al.* Cost and radiation savings of partial substitution of ultrasound for CT in appendicitis evaluation: A national projection. *Am J Roentgenol* 2014; 202(1): 124–135. doi: 10.2214/AJR.12.9642.
 24. Miglioretti DL, Johnson E, Williams A, Greenlee RT, Weinmann S, *et al.* The use of computed tomography in paediatrics and the associated radiation exposure and estimated cancer risk. *JAMA Pediatr* 2013; 167(8): 700–707. doi: 10.1001/jamapediatrics.2013.311.
 25. Howell JM, Eddy OL, Lukens TW, Thiessen MEW, Weingart SD, *et al.* Clinical policy: Critical issues in the evaluation and management of emergency department patients with suspected appendicitis. *Ann Emerg Med* 2010; 55(1): 71–116. doi: 10.1016/j.annemergmed.2009.10.004.
 26. Toorenvliet B, Vellekoop A, Bakker R, Wiersma F, Mertens B, *et al.* Clinical differentiation between acute appendicitis and acute mesenteric lymphadenitis in children. *Eur J Pediatr Surg* 2011; 21(2): 120–123. doi: 10.1055/s-0030-1267979.
 27. Yildirim E, Karagülle E, Kirbaş I, Türk E, Hasdoğan B, *et al.* Alvarado scores and pain onset in relation to multislice CT findings in acute appendicitis. *Diagn Interv Radiol* 2008; 14(1): 14–18.
 28. Mandeville K, Pottker T, Bulloch B, Liu J. Using appendicitis scores in the pediatric ED. *Am J Emerg Med* 2011; 29(9): 972–977. doi: 10.1016/j.ajem.2010.04.018.