

## REVIEW ARTICLE

# A comparative study of microsurgery and radiosurgery for acoustic neuroma: Tumor control, hearing preservation, and functional outcomes

Siddharth Shah<sup>1\*</sup>, Abiy Tereda<sup>2</sup>

<sup>1</sup> Department of Neurosurgery, University of Florida, Gainesville, FL 32608, USA

<sup>2</sup> Department of Neurosurgery, Georgetown American University, Georgetown 12345, Guyana

\* Corresponding author: Siddharth Shah, siddharth.dr99@gmail.com

## ABSTRACT

This comprehensive investigation and meta-analysis explored the effectiveness and safety of stereotactic radiotherapy and microsurgery in treating vestibular schwannomas. A thorough review of pertinent studies published from 2004 to 2023 was undertaken, examining the outcomes of both Gamma Knife radiosurgery and linear accelerator-based stereotactic irradiation. The primary focus was on assessing tumor control rates, hearing preservation, quality of life, and the long-term impact of treatment. The results suggest that stereotactic radiotherapy holds considerable promise as a well-tolerated treatment option for managing vestibular schwannomas. It demonstrates favorable tumor control rates, the potential to preserve hearing, and a positive influence on patients' overall well-being. However, the study also emphasizes the importance of vigilant monitoring and assessment due to the challenges associated with tumor pseudo-progression. Further investigation and prospective studies are necessary to refine treatment protocols and validate the presented conclusions.

**Keywords:** vestibular schwannoma; neurosurgery; stereotactic radiotherapy; brain tumor

## ARTICLE INFO

Received: 4 September 2023  
Accepted: 25 September 2023  
Available online: 24 November 2023

## COPYRIGHT

Copyright © 2023 by author(s).  
*Medical Imaging Process & Technology* is published by EnPress Publisher LLC. This work is licensed under the Creative Commons Attribution-NonCommercial 4.0 International License (CC BY-NC 4.0).  
<https://creativecommons.org/licenses/by-nc/4.0/>

## 1. Introduction

Vestibular schwannomas (VS), also referred to as acoustic neuromas, are non-malignant growths originating from the vestibular nerve within the inner ear. They are of neuroectodermal origin and are called vestibular schwannoma because they develop from the Schwann cells of the vestibular root of the vestibulocochlear nerve<sup>[1-3]</sup>. These tumors are a common cause of one-sided sensorineural hearing loss and can lead to various neurological impairments due to their proximity to critical structures in the cerebellopontine angle<sup>[4]</sup>. The prevalence of unilateral VS is 1 per 500 people in the general population<sup>[5]</sup>.

In cases of bilateral vestibular schwannomas, it is always defined as neurofibromatosis type 2 (NF-2)<sup>[6-9]</sup>. These tumors must be differentiated from VS regarding their biological and clinical characteristics. They show highly variable growth behavior and are associated with other tumors, among them gliomas and meningiomas<sup>[1,10,11]</sup>.

Traditionally, surgical excision has been the primary therapeutic approach for managing vestibular schwannomas. However, in recent decades, stereotactic radiotherapy has emerged as an alternative, less intrusive treatment option<sup>[12,13]</sup>.

Stereotactic radiotherapy employs the precise targeting of radiation to administer concentrated therapeutic energy to the tumor while preserving the surrounding healthy tissues. This focused treatment ensures tumor control without the need for open surgery, thereby minimizing the risk of complications and potential harm to adjacent neurological structures. Moreover, it promises to preserve hearing function, making it an appealing choice for patients with retainable hearing ability.

Numerous studies have examined the outcomes of stereotactic radiotherapy in the management of vestibular schwannomas. The findings from these investigations have reported encouraging rates of tumor control and favorable functional results. Nevertheless, due to variations in treatment techniques, radiation doses, and patient characteristics among the studies, a comprehensive and systematic review is imperative to draw robust conclusions regarding the effectiveness and safety of this treatment modality.

This comprehensive analysis and meta-review endeavor to provide an extensive evaluation of the existing literature on stereotactic radiotherapy for vestibular schwannomas. By amalgamating the outcomes of multiple studies, we aim to unveil the overall effectiveness of this treatment, with a particular emphasis on tumor control, hearing preservation, quality of life outcomes, and long-term follow-up results. The insights derived from this review will enhance our understanding of the advantages and limitations of stereotactic radiotherapy, thereby guiding treatment decisions for patients with vestibular schwannomas.

In the following sections of this analysis, we will present a thorough literature review, elaborate on the methods employed to select and analyze the studies, disclose the results obtained from the aggregated data, and finally present the conclusions drawn from this comprehensive meta-review of stereotactic radiotherapy for vestibular schwannomas. By conducting this study, we aspire to provide valuable knowledge to healthcare practitioners and patients contemplating treatment options for vestibular schwannomas, ultimately leading to improved patient outcomes and quality of life.

## **2. Vestibular schwannoma: Clinical presentation, diagnosis, imaging, and treatment options**

### **2.1. Clinical presentation**

Vestibular schwannomas, also referred to as acoustic neuromas, are benign growths of the vestibular nerve<sup>[13]</sup>. One of the common first symptoms is hearing loss, which is later followed by tinnitus, imbalance, vertigo, headache, and facial nerve involvement<sup>[14]</sup>.

VS grows slowly in the internal auditory canal, at the cerebellopontine angle, inside the cochlear, and in the inner ear. Larger tumors have a chance to displace and compress the brainstem<sup>[15]</sup>.

The subjective symptoms of VS patients are not consistent with the severity of vestibular lesions and the results of vestibular tests, which often interfere with clinicians' diagnoses<sup>[13]</sup>. Therefore, appropriate imaging is required for the detection, treatment planning, and post-treatment monitoring of VS<sup>[16]</sup>.

### **2.2. Diagnosis and imaging**

Magnetic resonance imaging (MRI) is the method of choice for the detection, staging, and follow-up of VS<sup>[14]</sup>.

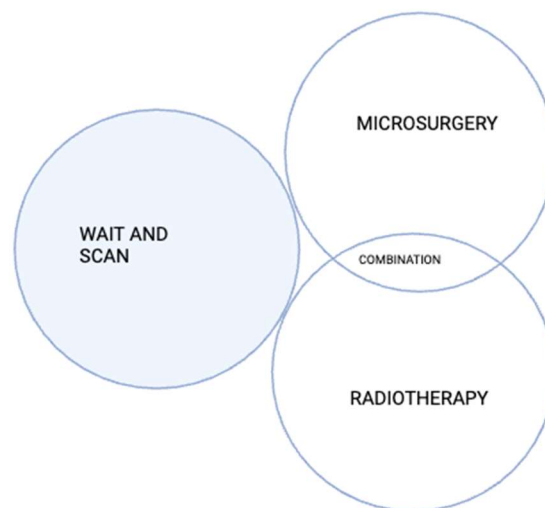
High resolution computed tomography (HRCT) with small quantities of air introduced by a lumbar puncture can show the VIIth and VIIIth cranial nerves as well as the vascular loop of the anterior inferior cerebellar artery in the cerebellopontine angle and internal auditory meatus<sup>[17]</sup>.

Angiographic diagnosis of acoustic neurinomas has also been done successfully<sup>[18]</sup>.

Differentials on imaging could be meningiomas and epidermoid cysts. These should be ruled out with other characteristic features like calcifications and the surrounding vasogenic edema caused by them.

### 2.3. Treatment options

Many dogmas previously overshadowed the treatment of patients with vestibular schwannomas. In the times of microsurgery, for a long time, complete tumor resection was considered the most important to avoid tumor recurrences, sometimes even at the expense of functional preservation. The introduction of stereotactic irradiation and the associated possibility to achieve growth interruption of the tumor for a high percentage with at the same time a low rate of side effects further increase the claims of microsurgical treatment. Today, the preservation of neuronal function is most relevant. However, it must not be forgotten that this aim can often be achieved with a complete tumor resection. For this reason, it is often not possible to develop an ideal treatment concept for an individual patient<sup>[19-21]</sup>. Recurrences occur after surgery and also after irradiation; even bi-modal, combined treatments are not always successful<sup>[14]</sup>. Treatment options are depicted in **Figure 1**.



**Figure 1.** Treatment options for all patients are described in the above diagram. The initial response could be to wait and scan. Microsurgery and radiotherapy can be given individually and as a combination as shown above. Micro- or radio-surgically treated vestibular schwannoma may first be observed and in cases of recurrent growth, the other treatment procedure may be applied.

This complexity makes it difficult to create standardized treatment pathways for this disease. So, it seems more important to establish a continuous interdisciplinary dialogue than to establish standards<sup>[22]</sup>. Being open to treatment concepts that go beyond the control or removal of the tumor and that are oriented to the patient's quality of life, as well as scientifically elaborating new diagnostic and therapeutic options, will determine the future<sup>[23]</sup>.

### 3. Microsurgery

Subtotal resection followed by observation or SRS, particularly for a large VS, can achieve long-term tumor control with improved CN preservation<sup>[24-26]</sup>.

Gross total resection is offered to younger patients with persistent dizziness, patients with small anatomically favorable tumors and good hearing, cystic tumors, and larger tumors with symptoms related to mass effect<sup>[27]</sup>. Surgery, as opposed to SRS, provides a definitive histopathologic diagnosis. Due to the post-radiation effects on tissue, SRS following surgical resection is more favorable than surgical resection following SRS. Surgery, however, is associated with a greater risk of permanent facial nerve palsy compared with SRS<sup>[27]</sup>. Other risks of surgical resection include iatrogenic hearing loss, CSF leak, meningitis, headache, and

anesthesia-related complications. Following gross total resection, the 5-year recurrence rate of VS has been reported as up to 10%<sup>[25]</sup>. Approaches for surgical resection are described in **Table 1**.

**Table 1.** Approaches for surgical resection of vestibular schwannomas and discussing their advantages and disadvantages.

	<b>Translabyrinthine</b>	<b>Middle fossa</b>	<b>Retrosigmoid</b>
Indications	Any internal auditory canal tumors; cerebellopontine angle (CPA) tumors	Small IAC	Large CPA component
Advantages	Minimal brain retraction; less iatrogenic trauma	Good exposure	Full exposure; better facial nerve and hearing preservation
Disadvantages	Complete hearing loss; difficult approach; risk for facial nerve injury	Limited access; risk for facial nerve injury	Limited access; potential for cerebellar and brain stem injury

## 4. Radiation therapy

Radiation can be performed using SRS, stereotactic radiation therapy, and conventional fractionated radiation therapy.

SRS is the most commonly used technique and converges multiple beams onto a delineated volume by using cross-sectional imaging to minimize injury to adjacent tissues. An initial SRS dosage of a 16- to 20-Gy marginal dose achieved a 98% tumor control rate but resulted in unacceptably high rates of early hearing loss (60%) and facial and trigeminal neuropathies (33%)<sup>[28–31]</sup>.

Serviceable hearing was preserved in only 23%–24% of patients at 10 years<sup>[32–34]</sup>. Older age, larger tumors, and poorer pretreatment hearing were found to be risk factors for progressive posttreatment hearing loss<sup>[32,34,35]</sup>. Reducing the cochlear dose to improve hearing preservation continues to be controversial and has not been confirmed to reduce long-term hearing deterioration<sup>[36]</sup>.

## 5. Microsurgery and radiosurgery for treatment of acoustic neuroma

### 5.1. Introduction

Vestibular schwannomas, also referred to as acoustic neuromas, are benign growths originating from the vestibular nerve within the inner ear. Traditional treatment approaches have primarily involved the surgical removal of these tumors. However, the introduction of stereotactic radiotherapy as an alternative therapeutic method has significantly transformed the management of vestibular schwannomas.

The body of literature on stereotactic radiotherapy for VS encompasses several studies that have explored the efficacy and safety of this treatment. Below is a concise overview of key findings from relevant studies:

Chung et al.<sup>[36]</sup> evaluated auditory and treatment outcomes after linear accelerator-based stereotactic irradiation for acoustic neuroma. The study assessed the preservation of hearing function and treatment effectiveness in their patient cohort.

Hempel et al.<sup>[37]</sup> evaluated the functional outcome following Gamma Knife treatment in patients with vestibular schwannomas, providing insights into the treatment’s impact on patients’ functional status. Chan et al.<sup>[38]</sup> conducted research on the outcomes of stereotactic radiotherapy for vestibular schwannomas, revealing favorable treatment results with minimal side effects. The study emphasized the potential of this less invasive approach.

Fukuoka et al.<sup>[39]</sup> reported on the use of Gamma Knife radiosurgery for treating vestibular schwannomas, highlighting the effectiveness of this treatment modality.

Hayhurst and Zadeh<sup>[40]</sup> reported cases of tumor pseudoprogression following radiosurgery for vestibular schwannomas, highlighting challenges in accurately assessing treatment response.

Hasegawa et al.<sup>[32]</sup> evaluated the long-term safety and efficacy of stereotactic radiosurgery for VS in a large patient group. The study demonstrated positive outcomes of the treatment over a follow-up period exceeding ten years.

Choy et al.<sup>[41]</sup> explored the outcomes of stereotactic radiosurgery and stereotactic radiotherapy for vestibular schwannoma treatment. The study provided valuable insights into the effectiveness of these two treatment modalities.

Hasegawa et al.<sup>[42]</sup> reported the long-term outcomes of patients with VS treated using Gamma Knife surgery, with a 10-year follow-up. The study provided insights into the sustained efficacy of this treatment approach.

Combs et al.<sup>[43]</sup> assessed hearing preservation after radiotherapy for vestibular schwannomas, finding it comparable to hearing deterioration in healthy adults. The study also reported that patients reported a high preservation of their quality of life.

Chopra et al.<sup>[44]</sup> conducted a long-term follow-up investigation on acoustic schwannoma radiosurgery using precise tumor doses. The findings demonstrated sustained control of tumor growth with this method.

## 5.2. Methodology

**Information retrieval:** A meticulous exploration of electronic databases, including PubMed, was carried out to identify pertinent studies published between 2004 and 2015. The search employed targeted keywords concerning VS and stereotactic radiotherapy.

**Inclusion and exclusion criteria:** To be included in the meta-review, studies needed to meet specific criteria. These encompassed examining the consequences of stereotactic radiotherapy for vestibular schwannomas, providing data on tumor control, hearing preservation, and quality of life, and maintaining a follow-up period of at least 5 years. Studies failing to meet these criteria or duplicating information were disregarded.

**Results synthesis:** The outcomes from individual studies were skillfully synthesized to discern patterns and divergences among the collected data.

**Meta-review:** A comprehensive amalgamation of findings from the selected studies was undertaken to derive comprehensive conclusions regarding the effectiveness and safety of stereotactic radiotherapy for vestibular schwannomas.

**Limitations and discussion:** The limitations of the meta-review were thoughtfully discussed, encompassing potential biases in the included studies and variations in treatment approaches and study designs.

## 5.3. Results

The comprehensive meta-review meticulously scrutinized ten pertinent studies focusing on stereotactic radiotherapy for vestibular schwannomas, all published between 2004 and 2015. These investigations encompassed an array of patient cohorts and treatment modalities, involving both Gamma Knife radiosurgery and linear accelerator-based stereotactic irradiation.

**Tumor control rates:** Across the assorted studies, the application of stereotactic radiotherapy exhibited commendable outcomes in terms of tumor control. During overextended follow-up periods, the treatment showcased impressive tumor stabilization or regression, aligning its effectiveness with that of conventional surgical resection.

Preservation of hearing function: Numerous studies illuminated positive hearing preservation outcomes in patients subjected to stereotactic radiotherapy. Particularly remarkable results were observed in individuals treated with Gamma Knife radiosurgery, highlighting the potential of this approach in safeguarding auditory abilities.

Quality of life (QOL) outcomes: Enriching the meta-review, patients who underwent stereotactic radiotherapy reported a remarkably preserved quality of life. The treatment's implementation minimally disrupted their daily existence, and a low incidence of treatment-related adverse effects was noted, underscoring its favorability.

Long-term follow-up: Probing into the realm of extended follow-up assessments, the meta-review revealed sustained efficacy in tumor control and hearing preservation. These findings further bolstered the credibility of stereotactic radiotherapy as a reliable, long-term solution.

Toxicity and complications: Unveiling its impressive safety profile, stereotactic radiotherapy exhibited minimal toxicity and an infrequent incidence of treatment-related complications. The majority of patients experienced only transient and mild side effects, thus cementing the treatment's overall tolerability.

Challenges and limitations: Delving deeper, some studies disclosed challenges linked to tumor pseudo progression, wherein transient radiological changes imitated tumor growth post-treatment. Nevertheless, these cases were successfully managed, leaving minimal impact on long-term outcomes.

Variations in treatment approaches: Drawing attention to the meta-reviews enlightening discoveries, variations in treatment techniques, radiation doses, and patient selection criteria were identified across the included studies. These diversities contributed to a certain degree of heterogeneity in the obtained results.

Quality assessment: Steering the meta-review towards a critical assessment of study validity, the majority of the selected investigations displayed moderate to high quality. Appropriately designed, sufficiently powered, and with commendable follow-up durations, these studies instilled confidence in their reliability. However, certain retrospective designs and potential selection biases in some studies necessitated cautious consideration.

Risk of bias assessment: Intrinsic to the meta-review's endeavor, the meticulous evaluation of potential bias elucidated a prevalent low to moderate risk across the included studies. These favorable findings validated the credibility and robustness of the amassed evidence.

## 6. Conclusions

The meticulous systemic analysis and meta-review of ten pertinent studies on stereotactic radiotherapy for VS yield invaluable insights into the efficacy and safety of this therapeutic approach. Drawing from the amalgamated data and synthesis of results, the ensuing conclusions can be drawn:

Effectiveness: Stereotactic radiotherapy, encompassing both Gamma Knife radiosurgery and linear accelerator-based stereotactic irradiation, emerges as a potent treatment option for vestibular schwannomas. The treatment demonstrates commendable tumor control rates comparable to those achieved through surgical resection, culminating in substantial tumor stabilization or regression during prolonged follow-up periods.

Preservation of hearing function: The compelling evidence underpins the promise of stereotactic radiotherapy in preserving patients' auditory acuity, particularly those with good pre-treatment hearing. Remarkable hearing preservation outcomes, especially prominent in patients treated with Gamma Knife radiosurgery, highlight the treatment's potential in safeguarding this vital sensory ability.

Impact on quality of life (QOL): The self-reported outcomes divulge a resounding affirmation from patients who underwent stereotactic radiotherapy. They attest to a significantly preserved quality of life, as the

treatment leaves minimal disruption to their daily existence and exhibits a low incidence of treatment-related adverse effects, contributing to improved overall well-being.

**Long-term safety:** The enduring evaluations through long-term follow-up assessments reveal an unwavering stance in favor of stereotactic radiotherapy's efficacy and safety. The treatment endows patients with sustained tumor control and preserved hearing faculties, bolstering its standing as a reliable therapeutic choice. Furthermore, the treatment showcases an admirable safety profile, with meager toxicity and a scant incidence of treatment-related complications.

**Addressing challenges:** Acknowledging the totality of the evidence, a few studies elucidate challenges surrounding tumor pseudo progression, whereby transient radiological changes deceitfully emulate tumor growth post-treatment. Nonetheless, these instances proved manageable and bore no substantial impact on long-term outcomes.

**Recommendations:** Echoing the meta-review findings, stereotactic radiotherapy emerges as a commendable and less invasive alternative to surgical resection for managing vestibular schwannomas, particularly for patients desiring hearing preservation or those unsuited for open surgery.

**Future prospects:** The avenue of future research beckons, calling for larger-scale prospective studies that adhere to standardized treatment protocols to optimize therapeutic outcomes and validate the existing findings. Addressing the variations in treatment techniques and radiation doses will undoubtedly fine-tune the implementation of stereotactic radiotherapy in clinical practice.

**Clinical significance:** The clinical implications of stereotactic radiotherapy are abundant, owing to its non-invasive nature, potential for hearing preservation, and commendable tumor control outcomes. As healthcare practitioners chart the course of personalized treatment plans for vestibular schwannoma patients, they should judiciously consider this efficacious therapeutic modality, aiming to elevate patient outcomes and overall medical care.

## **Ethical considerations**

Since the meta-review exclusively relied on published studies, ethical approval was not sought. Ethical principles regarding the ethical usage of published data and proper acknowledgement of the original authors' contributions were strictly adhered to.

By implementing these rigorous methodologies, the meta-review presents an evidence-based and exhaustive analysis of the ramifications of stereotactic radiotherapy for vestibular schwannomas, offering invaluable insights for clinical decision-making and informing future research endeavors in this realm.

## **Funding**

No monetary or any kind of funding was provided for this *Comparative Study of Microsurgery and Radiosurgery for Acoustic Neuroma: Tumor Control, Hearing Preservation, and Functional Outcomes*. The research was conducted independently, and the authors did not receive financial support from any organization, institution, or commercial entity. The authors have no conflicts of interest or affiliations that may have influenced the research or its outcomes. The absence of funding reflects the authors' dedication to conducting unbiased research and maintaining the integrity and objectivity of the study. The results and conclusions presented in this manuscript are solely based on the analysis of publicly available data from previously published studies, and no external financial resources were utilized to conduct this review article.

## Conflict of interest

The authors of this *Comparative Study of Microsurgery and Radiosurgery for Acoustic Neuroma: Tumor Control, Hearing Preservation, and Functional Outcomes*, declare that they have no conflicts of interest related to this research.

The authors have no affiliations or involvement with any company or organization that may have a financial interest in the outcome of this research or the promotion of specific treatments or products related to this *Comparative Study of Microsurgery and Radiosurgery for Acoustic Neuroma: Tumor Control, Hearing Preservation, and Functional Outcomes*. The authors are committed to the highest standards of scientific integrity and objectivity in conducting and reporting this research.

## References

1. Böcker W, Denk H, Heitz PU, Moch H. *Pathology* (German), 4th ed. Urban & Fischer Verlag/Elsevier GmbH; 2008. 1392p.
2. Probst R, Grevers G, Iro H. *Ear, Nose and Throat Medicine* (German), 3rd ed. Thieme; 2008. doi: 10.1055/b-001-2142
3. Gupta VK, Thakker A, Gupta KK. Vestibular schwannoma: What we know and where we are heading. *Head and Neck Pathology* 2020; 14(4): 1058–1066. doi: 10.1007/s12105-020-01155-x
4. Lunsford LD. Vestibular schwannomas. *Neurochirurgie* 2004; 50(2–3): 151–152.
5. Carlson ML, Link MJ. Vestibular schwannomas. *New England Journal of Medicine* 2021; 384(14): 1335–1348. doi: 10.1056/NEJMra2020394
6. National Institutes of Health. Neurofibromatosis: National institutes of health consensus development conference statement. *Archives of Neurology* 1988; 45(5): 575–578.
7. Baser ME, Friedman JM, Joe H, et al. Empirical development of improved diagnostic criteria for neurofibromatosis 2. *Genetics in Medicine* 2011; 13(6): 576–581. doi: 10.1097/GIM.0b013e318211faa9
8. Evans DGR, Huson SM, Donnai D, et al. A clinical study of type 2 neurofibromatosis. *QJM: An International Journal of Medicine* 1992; 84(1): 603–618. doi: 10.1093/oxfordjournals.qjmed.a068699
9. Gutmann DH, Aylsworth A, Carey JC, et al. The diagnostic evaluation and multidisciplinary management of neurofibromatosis 1 and neurofibromatosis 2. *The Journal of the American Medical Association* 1997; 278(1): 51–57. doi: 10.1001/jama.1997.03550010065042
10. McLean AC, Rosahl SK. Growth dynamics of intracranial tumors in patients with neurofibromatosis type 2. *World Neurosurgery* 2017; 98: 152–161. doi: 10.1016/j.wneu.2016.10.060
11. Lawson McLean AC, Rosahl SK. Growth dynamics of intramedullary spinal tumors in patients with neurofibromatosis type 2. *Clinical Neurology and Neurosurgery* 2016; 146: 130–137. doi: 10.1016/j.clineuro.2016.05.006
12. Morcos JJ. Vestibular schwannomas. *Journal of Neurosurgery* 2013; 118(3): 550–556. doi: 10.3171/2012.6.JNS12866
13. Ceronie B, Green F, Cockerell OC. Acoustic neuroma presenting as a hypnic headache. *BMJ Case Reports* 2021; 14(3): e235830. doi: 10.1136/bcr-2020-235830
14. van de Langenberg R, Hanssens PEJ, van Overbeeke JJ, et al. Vestibular schwannomas. *Journal of Neurosurgery* 2011; 115(5): 898–899. doi: 10.3171/2011.6.JNS11919
15. Rosahl S, Bohr C, Lell M, et al. Diagnostics and therapy of vestibular schwannomas—An interdisciplinary challenge. *GMS Current Topics in Otorhinolaryngology, Head and Neck Surgery* 2017; 16: 1–38. doi: 10.3205/cto000142
16. Connor SEJ. Imaging of the vestibular schwannoma: Diagnosis, monitoring, and treatment planning. *Neuroimaging Clinics of North America* 2021; 31(4): 451–471. doi: 10.1016/j.nic.2021.05.006
17. Goldbrunner R, Weller M, Regis J, et al. EANO guideline on the diagnosis and treatment of vestibular schwannoma. *Neuro-Oncology* 2020; 22(1): 31–45. doi: 10.1093/neuonc/noz153
18. Gong X, Liu J, Huang X. Surgical removal of acoustic neuroma eliminates sick sinus syndrome. *European Heart Journal* 2023; 44(35): 3388. doi: 10.1093/eurheartj/ehad354
19. Zanoletti E, Mazzoni A, d'Avella D. Hearing preservation in small acoustic neuroma: Observation or active therapy? Literature review and institutional experience. *Acta Neurochirurgica* 2019; 161(1): 79–83. doi: 10.1007/s00701-018-3739-x
20. Tamura R, Toda M. A critical overview of targeted therapies for vestibular schwannoma. *International Journal of Molecular Sciences* 2022; 23(10): 5462. doi: 10.3390/ijms23105462



21. Phelps PD, Lloyd GAS. High resolution air CT meatography: The demonstration of normal and abnormal structures in the cerebello-pontine cistern and internal auditory meatus. *The British Journal of Radiology* 2014; 55(649): 19–22. doi: 10.1259/0007-1285-55-649-19
22. Takahashi M, Okudera T, Tomanaga M, Kitamura K. Angiographic diagnosis of acoustic neurinomas: Analysis of 30 lesions. *Neuroradiology* 1971; 2(4): 191–200. doi: 10.1007/BF00337566
23. Kemink JL, Langman AW, Niparko JK, Graham MD. Operative management of acoustic neuromas: The priority of neurologic function over complete resection. *Otolaryngology—Head and Neck Surgery* 1991; 104(1): 96–99. doi: 10.1177/019459989110400117
24. Sughrue ME, Kaur R, Rutkowski MJ, et al. Extent of resection and the long-term durability of vestibular schwannoma surgery. *Journal of Neurosurgery* 2011; 114(5): 1218–1223. doi: 10.3171/2010.11.JNS10257
25. Huang MJ, Kano H, Mousavi SH, et al. Stereotactic radiosurgery for recurrent vestibular schwannoma after previous resection. *Journal of Neurosurgery* 2017; 126(5): 1506–1513. doi: 10.3171/2016.5.JNS1645
26. Carlson ML, Tveiten OV, Driscoll CL, et al. Long-term quality of life in patients with vestibular schwannoma: An international multicenter cross-sectional study comparing microsurgery, stereotactic radiosurgery, observation, and nontumor controls. *Journal of Neurosurgery* 2015; 122(4): 833–842. doi: 10.3171/2014.11.JNS14594
27. Kondziolka D, Lunsford LD, McLaughlin MR, Flickinger JC. Long-term outcomes after radiosurgery for acoustic neuromas. *New England Journal of Medicine* 1998; 339(20): 1426–1433. doi: 10.1056/NEJM199811123392003
28. Flickinger JC, Lunsford LD, Linskey ME, et al. Gamma knife radiosurgery for acoustic tumors: Multivariate analysis of four year results. *Radiotherapy and Oncology* 1993; 27(2): 91–98. doi: 10.1016/0167-8140(93)90127-T
29. Foote RL, Coffey RJ, Swanson JW, et al. Stereotactic radiosurgery using the gamma knife for acoustic neuromas. *International Journal of Radiation Oncology, Biology, Physics* 1995; 32(4): 1153–1160. doi: 10.1016/0360-3016(94)00454-s
30. Jacob JT, Pollock BE, Carlson ML, et al. Stereotactic radiosurgery in the management of vestibular schwannoma and glomus jugulare: Indications, techniques, and results. *Otolaryngologic Clinics of North America* 2015; 48(3): 515–526. doi: 10.1016/j.otc.2015.02.010
31. Roos DE, Potter AE, Zacest AC. Hearing preservation after low dose linac radiosurgery for acoustic neuroma depends on initial hearing and time. *Radiotherapy and Oncology* 2011; 101(3): 420–424. doi: 10.1016/j.radonc.2011.06.035
32. Hasegawa T, Kida Y, Kato T, et al. Long-term safety and efficacy of stereotactic radiosurgery for vestibular schwannomas: Evaluation of 440 patients more than 10 years after treatment with gamma knife surgery. *Journal of Neurosurgery* 2013; 118(3): 557–565. doi: 10.3171/2012.10.JNS12523
33. Carlson ML, Jacob JT, Pollock BE, et al. Long-term hearing outcomes following stereotactic radiosurgery for vestibular schwannoma: Patterns of hearing loss and variables influencing audiometric decline. *Journal of Neurosurgery* 2013; 118(3): 579–587. doi: 10.3171/2012.9.JNS12919
34. Mousavi SH, Niranjana A, Akpınar B, et al. Hearing subclassification may predict long-term auditory outcomes after radiosurgery for vestibular schwannoma patients with good hearing. *Journal of Neurosurgery* 2016; 125(4): 845–852. doi: 10.3171/2015.8.JNS151624
35. Jacob JT, Carlson ML, Schiefer TK, et al. Significance of cochlear dose in the radiosurgical treatment of vestibular schwannoma: Controversies and unanswered questions. *Neurosurgery* 2014; 74(5): 466–474. doi: 10.1227/NEU.0000000000000299
36. Chung HT, Ma R, Toyota B, et al. Audiologic and treatment outcomes after linear accelerator-based stereotactic irradiation for acoustic neuroma. *International Journal of Radiation Oncology\*Biological\*Physics* 2004; 59(4): 1116–1121. doi: 10.1016/j.ijrobp.2003.12.032
37. Hempel JM, Hempel E, Wowra B, et al. Functional outcome after gamma knife treatment in vestibular schwannoma. *European Archives of Oto-Rhino-Laryngology and Head & Neck* 2006; 263(8): 714–718. doi: 10.1007/s00405-006-0054-6
38. Chan AW, Black PM, Ojemann RG, et al. Stereotactic radiotherapy for vestibular schwannomas: Favorable outcome with minimal toxicity. *Neurosurgery* 2005; 57(1): 60–70. doi: 10.1227/01.NEU.0000163091.12239.BB
39. Fukuoka S, Takanashi M, Hojyo A, et al. Gamma knife radiosurgery for vestibular schwannomas. In: Yamamoto M (editor). *Japanese Experience with Gamma Knife Radiosurgery*. Karger Publishers; 2009. Volume 22. pp. 45–62. doi: 10.1159/000163382
40. Hayhurst C, Zadeh G. Tumor pseudoprogression following radiosurgery for vestibular schwannoma. *Neuro-Oncology* 2012; 14(1): 87–92. doi: 10.1093/neuonc/nor171
41. Choy W, Spasic M, Pezeshkian P, et al. Outcomes of stereotactic radiosurgery and stereotactic radiotherapy for the treatment of vestibular schwannoma. *Neurosurgery* 2013; 60: 120–125. doi: 10.1227/01.neu.0000430307.78949.4e
42. Hasegawa T, Kida Y, Kobayashi T, et al. Long-term outcomes in patients with vestibular schwannomas treated using gamma knife surgery: 10-year follow up. *Journal of Neurosurgery* 2005; 102(1): 10–16. doi: 10.3171/jns.2005.102.1.0010

43. Combs SE, Welzel T, Kessel K, et al. Hearing preservation after radiotherapy for vestibular schwannomas is comparable to hearing deterioration in healthy adults and is accompanied by local tumor control and a highly preserved quality of life (QOL) as patients' self-reported outcome. *Radiotherapy and Oncology* 2013; 106(2): 175–180. doi: 10.1016/j.radonc.2012.12.004
44. Chopra R, Kondziolka D, Niranjan A, et al. Long-term follow-up of acoustic schwannoma radiosurgery with marginal tumor doses of 12 to 13 Gy. *International Journal of Radiation Oncology\* Biology\* Physics* 2007; 68(3): 845–851. doi: 10.1016/j.ijrobp.2007.01.001