

## ORIGINAL RESEARCH ARTICLE

# Doppler-echo guided angioplasty in the treatment of arterio-venous fistula stenosis for hemodialysis

Eduardo Mateos Torres<sup>1,2\*</sup>, Meritxell Mellado Joan<sup>1,2</sup>, Laura Calsina Juscafresa<sup>1</sup>, Carlos Ruiz Carmona<sup>1,2</sup>, Albert Clar á Velasco<sup>1,2</sup>

<sup>1\*</sup> *Servicio de Angiología y Cirugía Vascular; Institut Hospital del Mar d'Investigacions Mèdiques (IMIM), Hospital del Mar, Barcelona. E-mail: emateos@parcdesalutmar.cat*

<sup>2</sup> *Universitat Autònoma, Catalonia, Barcelona.*

---

### ABSTRACT

**Introduction:** Stenoses in the path of arteriovenous fistulas (AVF) for hemodialysis are a very prevalent problem and there is long experience in their treatment by percutaneous angioplasty (PTA). These procedures, however, involve non-negligible equipment requirements, exposure to radiation and intravenous contrast that are not beneficial for the patient and make their performance more complex. This study reviews our initial experience with Doppler ultrasound-guided angioplasty. **Methods:** Prospective cohort of patients with native AVF dysfunction due to significant venous stenosis treated by Doppler echo-guided PTA. AVF puncture, lesion catheterization, balloon localization and inflation, and outcome verification were performed under ultrasound guidance. Only one fistulography was performed before and another one after dilatation. As a control, the cases performed during the same period by the usual angiographic method were also collected. **Results:** Between February 2015 and September 2018, 51 PTAs were performed on native AVF, of which 27 were echogenic (mean age, 65.3 years; 63% male). The technical success rate was 96%. In 26% of cases, PTA was repeated due to residual stenosis after angiographic imaging. There were 7.3% periprocedural complications. 92% of the AVFs were punctured at 24 hours. Primary patency at 1 month, 6 months and 1 year was 100%, 64.8% and 43.6%, and assisted patency was 100%, 87.2% and 74.8%. There were no significant differences in immediate or late results with respect to angiographically guided AVF angioplasty. **Conclusions:** AVF-PTA can be performed safely and effectively guided by Doppler ultrasound, which simplifies the logistics required for its performance, although we still need to improve the capacity for early verification of the result with this imaging technique.

**Keywords:** Surgical Arteriovenous Shunt; Hemodialysis; Doppler Ultrasound; Angioplasty

---

### ARTICLE INFO

Received: 10 January 2022  
Accepted: 21 February 2022  
Available online: 4 March 2022

### COPYRIGHT

Copyright © 2022 by author(s).  
*Imaging and Radiation Research* is published by EnPress Publisher LLC. This work is licensed under the Creative Commons Attribution-NonCommercial 4.0 International License (CC BY-NC 4.0).  
<https://creativecommons.org/licenses/by-nc/4.0/>

## 1. Introduction

Stenoses in the path of arteriovenous fistulas (AVF) for hemodialysis (HD) are a very prevalent problem. They occur significantly in up to 42% of native AVFs<sup>[1,2]</sup>. There is long experience in their treatment by percutaneous angioplasty, a procedure that, however, involves not insignificant needs for processing, exposure to radiation and intravenous contrast that are not beneficial for the patient and make it more complex to perform.

The most recent guidelines<sup>[3,4]</sup> recommend Doppler ultrasound as the imaging examination of first choice to indicate elective treatment in the presence of any suspicion of significant stenosis. In these guidelines, angioplasty is also recommended for treatment of stenosis of the native AVF venous pathway, as it is less invasive than surgery. Taking these recommendations into account, it is logical to think that, if the diagnos-

tic option can be combined with the therapeutic option of choice, we could provide a benefit to the technique, as has already been described in the medical literature written by Bacchini *et al.*<sup>[5]</sup>, Wakabayashi *et al.*<sup>[6]</sup> and Leskovar *et al.*<sup>[7]</sup>.

The aim of this study was to evaluate our initial experience in native AVF angioplasty guided by Doppler ultrasound.

## 2. Patients and methods

Prospective cohort of patients undergoing native AVF angioplasty guided by Doppler ultrasound and angiography (ECO Group). Angioplasties in prosthetic accesses and central veins were excluded. Data were also collected from the cohort of patients who underwent the technique exclusively by angiography (RX group) in the same period as a control group to compare safety and efficacy. Assignment of patients to one or the other treatment group was not randomized, but the surgeon decided in each case the type of technique to be performed according to the type of lesion, its visualization by Doppler ultrasound and the availability of ultrasound equipment in the operating room.

Demographic variables (age, sex), clinical history (diabetes mellitus, arterial hypertension), nephrological data (active HD or predialysis, degree of urgency) and characteristics of the AVF were assessed: type of AVF (radiocephalic, humerus-cephalic or humerus-basilic), laterality, date of performance and location of the stenosis (juxta-anastomotic or in the vein pathway).

The diagnosis of stenosis and the decision on the type of intervention were based on clinical assessment and preoperative Doppler ultrasound. The ultrasound examination was performed using a 7–11 MHz linear transducer and LogIQ S7 Expert equipment (General Electric Healthcare, United States). Suspected hemodynamically significant stenosis was considered to exist at a point in the AVF if any of the following conditions were met: (1) a peak systolic velocity ratio greater than 3 between the point of maximum acceleration and the proximal normal vessel; (2) a decrease in diameter <50% in B-mode and aliasing by turbulence in color mode at that point; and (3) an AVF flow  $Q_a < 500$  ml/min calculated by echo-Doppler.

The intervention was performed on an outpatient basis and under local anesthesia. A 5F introducer, 0.035 hydrophilic guidewire and Oceanus (iVascular, Spain) or Advance (Cook Medical, United States) simple angioplasty balloons with inflation pressures of up to 22 atm were used. In the cases performed in an ultrasound-guided manner, the puncture technique, lesion catheterization, measurement, balloon placement and angioplasty were performed by echo-Doppler, using a 6–15 MHz linear transducer and SII equipment (Sonosite, United States). A previous fistulography with iodinated contrast (once the lesion was catheterized) and another after angioplasty were performed to confirm stenosis and final verification. Technical success was considered to be resolution of the lesion or a residual stenosis <30%. Intervention times and the dose of iodinated contrast agent used were recorded.

Post-procedure controls were performed clinically. Those patients in whom dysfunctional AVF was detected were evaluated by ultrasound. During follow-up, the first puncture date, patency, use for HD, reinterventions and the need for new vascular access (VA) were recorded.

Statistical analysis was performed using SPSS version 22 software. The mean was used for descriptive analysis, the standard deviation (SD) for quantitative variables, and the frequency and percentages for qualitative variables. Comparison between quantitative variables was performed using the Student's t-test and between qualitative variables, the chi-square test. Permeability analysis was performed using Kaplan-Meier survival curves and their comparison by means of the Log-Rank and Breslow tests. Multivariate analysis was performed using Cox regression.

## 3. Results

Of the 51 angioplasties performed on native AVF between February 2015 and September 2018, 27 were guided by echo Doppler (ECO Group): 21 were first interventions and 6, restenosis. The remaining 24 angioplasties were performed exclusively by angiographic control (RX Group). The baseline characteristics of the patients who underwent surgery with ultrasound control are de-

scribed in **Table 1**, with no significant differences compared to those who underwent surgery with angiographic control only.

**Table 1.** Patient's baseline characteristics

	ECO group (n = 27)	RX group (n = 24)	<i>p</i>
Age*	65.3 (14.7)*	71.4 (13.7)*	0.309
Gender (male)	17 (63%)	14 (58%)	0.453
Arterial hypertension	19 (79%)	22 (91%)	0.283
Diabetes mellitus	14 (52%)	13 (54%)	0.618
Predialysis	3 (11%)	5 (21%)	0.139

\*: Mean (standard deviation).

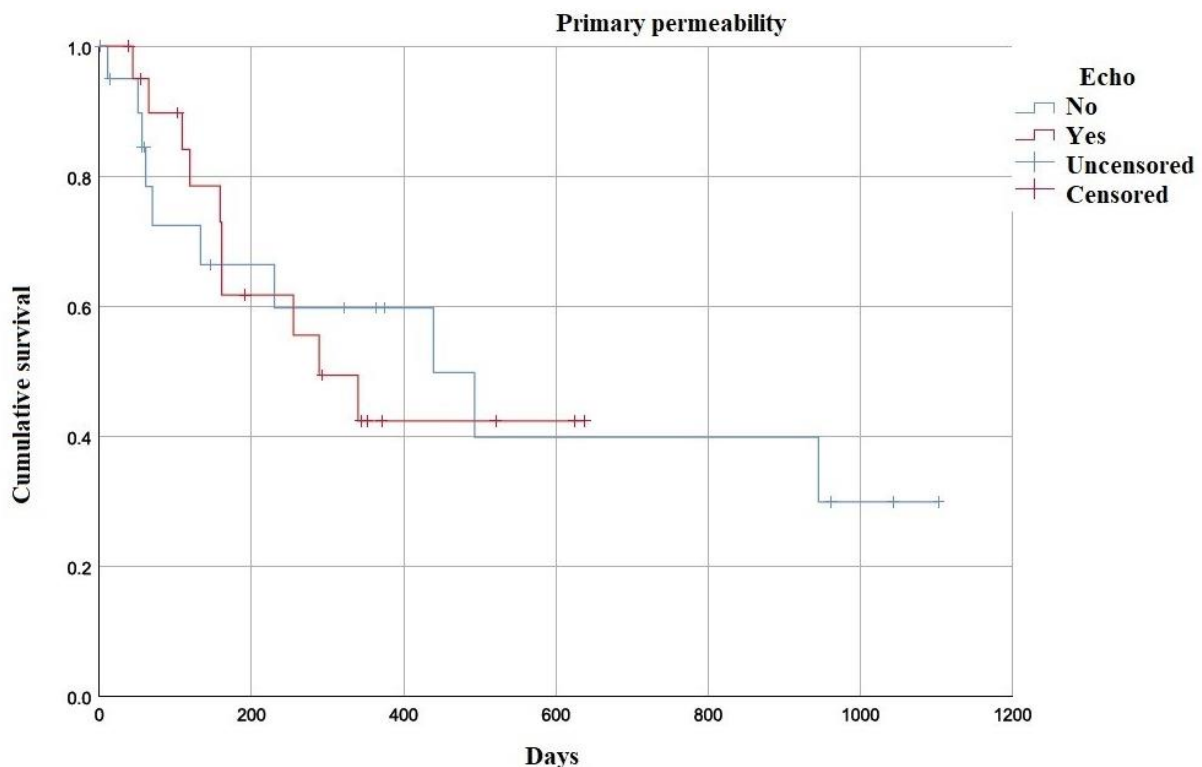
The type of VA operated on in the ECO group was 8 radiocephalic AVFs (30%), 16 humeromedial/cephalic (59%) and 3 humero-basilic (11%); the right arm was 59%. The location of the lesion was juxtastomotic in 16 cases (59%) and in the vein tract, in 11 (41%). No significant differences were observed in relation to those intervened only with angiographic control.

Regarding the administered dose of iodinated contrast, a mean of 23 ml (SD = 7.888) was used in the ECO Group, while in the RX Group it was 42 ml (SD = 19.497), a statistically significant difference ( $p < 0.001$ ). The mean intervention time in the ECO Group was 51 minutes (SD = 21.975), and in the RX Group, 57 (SD = 41.369), these differences

not being significant ( $p = 0.5015$ ).

Regarding the immediate results of the ultrasound-guided angioplasties, the technical success rate was 96% (in one patient with double stenosis, only one stenosis was successfully closed). In 7 cases (26%), angioplasty was repeated with a larger caliber balloon when an image of residual stenosis was observed in the angiographic check. The mean diameter of the balloon used was 5.13 mm. 92% of the AVFs could be punctured for HD on the same day or at 24 h, 1 was delayed to 8 days and 1 case was not punctured immediately because the patient was not yet in the HD program.

2 patients (7.4%) presented immediate complications: 1 rupture of the angioplasty vessel, which was corrected by implantation of a covered stent (Viabhan, 5 × 50 mm) and 1 hematoma at the puncture site that was resolved conservatively. Access patency was maintained in both cases. The mean AVF flow rate (Qa) measured on pre-Doppler echo was 433 ml/min (SD = 150), which increased statistically significantly to 1,154 ml/min (SD = 610) after the intervention ( $p = 0.017$ ). The mean follow-up was 392 days. Primary permeability at 1 month, 6 months and 1 year was 100%, 64.8% and 43.6%, respectively (**Figure 1**).

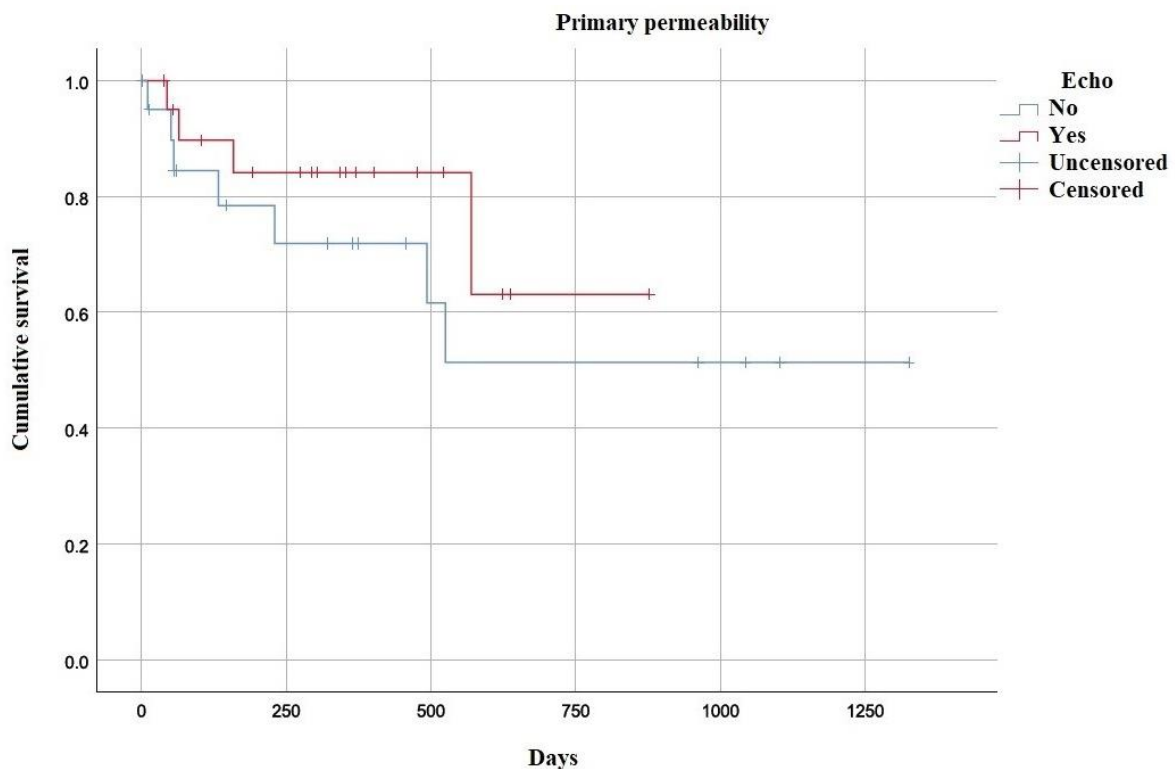


**Figure 1.** Primary patency of angioplasty guided by echo-Doppler (red) and angiography (blue).

During follow-up, to maintain VA function, 9 patients (33%) required additional interventions: 7 angioplasties for lesion restenosis (in one case on 2 occasions), 1 PTFE interposition in the stenotic zone, and 1 basilic vein superimposition. As a result, the rates of assisted patency at 1 month, 6 months and 1 year were 100%, 87.2% and 74.8% (**Figure 2**).

Three patients (11%) required a new AV during the first 6 months after the intervention, due to thrombosis or non-useful access. Two reanastomoses of the AVF proximal to the treated lesion and one AV prosthesis were performed. None of the

clinical variables assessed influenced the patency results in the multivariate Cox regression analysis. Regarding the results of the 24 native AVF angioplasties performed exclusively by angiographic control (RX group), the primary patency rates at 1 month, 6 months and 1 year were 95.0%, 66.3% and 59.7%, respectively; and the assisted patency rates were 95.0%, 78.4% and 71.9%, respectively, with no significant differences with respect to the group of echocardiographic angioplasties. There were also no differences in the intraoperative complication rate (9.7%).



**Figure 2.** Angioplasty-assisted patency guided by echo-Doppler (red) and angiography (blue).

## 4. Discussion

Doppler echo-guided angioplasty is a technique that has been described in the medical literature for years (the first series date back to 2000<sup>[5]</sup>), and has proven to be feasible to apply in vascular access for hemodialysis given that, due to their anatomical characteristics, the vessels of the upper extremities are easily explorable.

From the technical point of view, it requires significant practice in the handling and interpretation of the ultrasound, but with adequate training the elements of the AVF and the material used in the

technique can be distinguished precisely, which also facilitates navigation in a territory—the venous—that is often difficult to interpret by angiography. In addition, it has the advantage of providing not only anatomical information, but also hemodynamic information, with which we can have more data on the correct resolution of the lesion. This point has been one of the main limitations in our series, given that the ultrasound scanner available in the operating room could not be used to measure velocities and calculate vessel flow (Qa), so that angiographic verification of the result was essential at this stage. Having the appropriate

equipment is one of the requirements to be able to perform the technique exclusively with ultrasound, which would open the door to carrying it out in spaces other than an operating room or an angiography room, as long as sterile conditions are met.

A review of the literature found studies such as that of Ascher *et al.*<sup>[8]</sup>, who performed 32 angioplasties in 25 patients for immature accesses, with primary patency rates at 6 months of 53%. Gorin *et al.*<sup>[9]</sup> reported a 10% fistula loss after dilatation. But the most extensive series is that of the Japanese Masanori Wakabayashi<sup>[6]</sup>, who in 2013 reported 4,869 cases with immediate success in 97.1% of strictures. During the first year of his series, he required angiographic support in 25% of cases, although its use was subsequently anecdotal.

More recently, we found series such as those of García-Medina *et al.*<sup>[10]</sup>, who in 2016 published 189 PTA by ultrasound technique without the need for angiographic support in 67.2% of cases and with a primary patency at one year of 41%. Kumar's group<sup>[11]</sup> in 2017 performed 78 angioplasties with a success rate of 89.7% and a primary patency at one year of 60.2% and secondary patency of 100%; and in 2017 Leskovaar<sup>[7]</sup> presented 228 percutaneous PTA or as an adjunct in open surgical thrombectomies; 46% required a new angioplasty due to restenosis during follow-up.

Compared with the results of our series, patency and complications did not differ significantly from those reported in the literature or with the angiographic control group, with modest primary patency at 1 year, but assisted patency improves considerably if proper follow-up of VA is performed. In the recent GEMAV guidelines<sup>[3]</sup>, primary patency is cited at around 40–50%<sup>[12]</sup> of the technique performed using the usual angiographic technique, so that the results of the series guided by Doppler echocardiography would apparently not be inferior.

Regarding the technical differences with respect to the literature cited, in our series it was essential to verify the result angiographically, given the technical limitations of the equipment already mentioned, which did not allow the ultrasound verification to be performed reliably. The parameters of velocity and flow Qa are described as necessary, in

addition to the improvement of vessel diameter in B-mode<sup>[8]</sup>. Multiple studies report the need for angiographic support to confirm the result in up to 33% of the techniques<sup>[10]</sup>, but we do not know in our case how many would have required reconversion if they had been able to do it in optimal technical conditions. Despite this dependence on angiographic verification, as expected, the need for iodinated contrast was significantly lower with respect to the X-ray group, and did not increase the time required for the intervention.

Our study was limited by the small number of patients and the fact that they were not subject to randomization, but the main limitation was the dependence on angiographic control, given the technical impossibility of correct verification of the technique by means of a Doppler echo with adequate performance. As a result of this limitation, a quarter of the cases required a new angioplasty with a larger caliber balloon after the control fistulography during the same procedure. The fact that the final result was conditioned by the angiographic verification means that the comparison of permeability between techniques loses validity, but we thought it would be interesting to also reflect the results of the cases performed with angiographic control (X-ray group) in order to audit the safety and ensure that there was no reduction in the quality of the results offered to the patient.

We conclude, therefore, that angioplasty of AVF stenosis can be performed safely and effectively guided by Doppler ultrasound, which simplifies the logistics required for its performance, although we still need to improve the capacity for early verification of the result with this imaging technique.

## Conflict of interest

The authors declared no conflict of interest.

## References

1. Moreno Sánchez T, Martín Hervás C, Sola Martínez E, *et al.* Value of Doppler ultrasound in peripheral vascular access dysfunction for hemodialysis. *Radiología* 2014; 56(5): 420–428.
2. Salman L, Ladino M, Alex M, *et al.* Accuracy of ultrasound in the detection of inflow stenosis of arteriovenous fistulae: Results of a prospective study.

- Seminars in Dialysis 2010; 23(1): 117–121.
3. Ibeas J, Roca-Tey R, Vallespín J, *et al.* Spanish clinical guidelines on vascular access for haemodialysis. *Nefrología* 2017; 37(Supl.1): 1–191.
  4. Schmidli J, Widmer MK, Basile C, *et al.* Vascular access: 2018 clinical practice guidelines of the European society for vascular surgery (ESVS). *European Journal of Vascular and Endovascular Surgery* 2018; 55: 1–62.
  5. Bacchini G, Cappello A, La Milia V, *et al.* Color Doppler ultrasonography imaging to guide transluminal angioplasty of venous stenosis. *Kidney International* 2000; 58(4): 1810–1813.
  6. Wakabayashi M, Hanada S, Nakano H, *et al.* Ultrasound-guided endovascular treatment for vascular access malfunction: Results in 4,896 cases. *The Journal of Vascular Access* 2013; 14(3): 225–230.
  7. Leskovar B, Furlan T, Poznič S, *et al.* Ultrasound-guided percutaneous endovascular treatment of arteriovenous fistula/graft. *Clinical Nephrology* 2017; 88(7): 61–64.
  8. Ascher E, Hingorani A, Marks N. Duplex-guided balloon angioplasty of failing or non-maturing arterio-venous fistulae for hemodialysis: A new office-based procedure. *Journal of Vascular Surgery* 2009; 50(3): 594–599.
  9. Gorin DR, Perrino L, Potter DM, *et al.* Ultrasound-guided angioplasty of autogenous arteriovenous fistulas in the office setting. *Journal of Vascular Surgery* 2012; 55(6): 1701–1705.
  10. Garcia-Medina J, Garcia-Alfonso JJ. Ultrasound-guided angioplasty of dysfunctional vascular access for haemodialysis: The pros and cons. *Cardiovascular and Interventional Radiology* 2017; 40(5): 750–754.
  11. Kumar S, Mahajan N, Patil SS, *et al.* Ultrasound-guided angioplasty for treatment of peripheral stenosis of arteriovenous fistula—A single-center experience. *The Journal of Vascular Access* 2017; 18(1): 52–56.
  12. Mortamais J, Papillard M, Girouin N, *et al.* Endovascular treatment of juxta-anastomotic venous stenoses of forearm radiocephalic fistulas: Long-term results and prognostic factors. *Journal of Vascular and Interventional Radiology* 2013; 24(4): 558–564.