

ORIGINAL RESEARCH ARTICLE

Radiographic characteristics of dentigerous cysts diagnosed at the School of Stomatology of the Universidad Peruana Cayetano Heredia

Maria Alejandra Olaechea-Ramos*, Alexis Evangelista-Alva, Milushka Miroslava Quezada-Márquez

Universidad Peruana Cayetano Heredia, Perú. E-mail: maria.olaechea.r@upch.pe

ABSTRACT

Objective: To evaluate the radiographic characteristics of dentigerous cysts (DC) diagnosed at the School of Stomatology of the Universidad Peruana Cayetano Heredia (UPCH) during the period of 2010–2017. **Material and methods:** Retrospective, descriptive, observational and cross-sectional study, where the panoramic radiographs of 37 cases of DC were selected. **Results:** The total number of diagnosed cases of dentigerous cysts was 233, which after inclusion and exclusion criteria, 37 cases were obtained, of which 45.9% of cysts were found in the second decade of life with a higher frequency of 51.4 percent for women, and a jaw predilection of 59.5% in all cases. In addition, it was found that 97.3% of the cases were radiolucent, defined limits were found in 67.6%, corticalized edges in 54.1% and unilocular in 94.6%. All dentigerous cysts were associated with a tooth, of which closed apex (48.6%) and tooth displacement (59.5%) were observed. The adjacent tooth was not affected in 56.8% of cases, but its hard lamina was affected (59.5%). The 68.2% of cases did not affect the basal mandibular cortex, but did displace the inferior dental canal (54.5%) and 46.7% of cases displaced the floor of the maxillary sinus. **Conclusions:** Most of the results obtained on the characteristics in the Peruvian population support previous studies reported in America, Europe and Asia. Radiographically the dentigerous cyst showed characteristics that support its clearly benign behavior.

Keywords: Odontogenic Cysts; Dentigerous Cyst; Panoramic Radiography

ARTICLE INFO

Received: 28 May 2021
Accepted: 15 July 2021
Available online: 25 July 2021

COPYRIGHT

Copyright © 2021 by author(s).
Imaging and Radiation Research is published by EnPress Publisher LLC. This work is licensed under the Creative Commons Attribution-NonCommercial 4.0 International License (CC BY-NC 4.0).
<https://creativecommons.org/licenses/by-nc/4.0/>

1. Introduction

The dentigerous cyst (DC) is one of the most common odontogenic cysts that occur in the jaws^[1,2]. The term “dentigerous” means “containing a tooth” this means that it is related to the crown of impacted, submerged and unerupted teeth, adhered to the crown of these in the adamantine cement union (UCA) and grows by follicle expansion^[2-4], apparently in the absence of inflammatory stimuli so the presence of a crown inside the cyst is the frequent sign of the lesion^[4].

The radiological diagnosis of DC is simple, but it is necessary to differentiate it from a hyperplastic dental follicle. According to Devi et al. the normal follicular space measures 3 to 4 mm from the enamel surface to the edge of the lesion, when it is suspected that DC is often greater than 5 mm^[5].

The DC generally grows without presenting symptomatology and can exist without being discovered for years, so it tends to be a radiographic finding during the discard of an unerupted tooth^[1,6]. The epithelial cells that cover the lumen are capable of producing metaplastic changes, so some DC can progress to more aggressive lesions such as odontogenic keratocyst, ameloblastoma, mucoepidermoid carcinoma and primary intraosseous carcinoma^[2,7].

DC is a solitary entity, but it can present multiple or multifocal in the presence of syndromes or systemic conditions such as mucopolysaccharidosis, cleidocranial dysplasia, Gorlin-Goltz syndrome (vasocellular nevus syndrome), Maroteaux-Lamy and Klippel Feil syndrome. However, cases of DCs not associated with systemic conditions have been reported, being their location the same as that of a solitary DC^[5,8]. DCs have also been reported after prolonged use of cyclosporine A and calcium channel blockers^[5].

DC is caused by the pressure exerted by an erupting tooth within an impacted follicle, which obstructs the venous flow leading to a rapid transudate of serum through the walls of the blood capillaries, increasing the hydrostatic pressure of the fluid, resulting in the separation of the follicle from the crown with or without reduced enamel epithelium^[5].

Langlais classifies DCs with respect to the crown of the affected tooth as: eruption, circumferential and lateral cyst^[9]. There is a fourth variant called "inflammatory dentigerous cyst". The eruption cyst is a variant of the follicular cyst, which is close to the alveolar ridge. Clinically there is redness, increase of gum volume, which is the expansion of the lesion towards the soft tissues; the color of this lesion is due to the refractory property of the cystic fluid. Circumferential occurs when the associated tooth erupts or is erupting through the upper wall of the cyst.

In a lateral view, the cyst appears on both sides of the crown and may ultimately surround the roots of the associated tooth. The lateral is seen next to the involved tooth, moves to one side of the crown and this variant occurs when the tooth attempts to erupt. When this variant is distal or close to an impacted vertical mandibular third molar, it must be differentiated from a paradental cyst. The inflammatory variant arises from the spread of periapical inflammation from a non-vital primary tooth. This possibility was reported by Shaw in 1980. The most common sequela of untreated periapical inflammation in a primary tooth was intrafollicular penetration of inflammatory elements from the underlying permanent tooth. Subsequent proliferation of the

reduced enamel epithelium is stimulated by the inflammatory process.

The DC is the second most common cyst after the radicular cyst, representing 24% of all mandibular cysts^[5]. It predominantly affects males more than females, in a 2:1 ratio^[10]. The most affected teeth are the lower third molars, maxillary canines and premolars^[2]. Clinically, there is dental absence and areas of swelling, but without pain or discomfort, but with the presence of erythema. Likewise, on palpation there may be crepitus due to the expansion of the bony cortices, which is why the DC can reach a large size and we will see the patient with facial asymmetry^[11].

Radiographically, it appears as a well-defined radiolucent area with corticated edges and unilocular with a diameter greater than 2.5 cm around the crown of an unerupted tooth. It can cause root resorption of permanent or deciduous teeth and sometimes it is multilocular with scalloped or discontinuous margins^[2,3,6], and can be confused with another odontogenic lesion such as unicystic ameloblastoma, keratocyst, adenomatoid odontogenic tumor (AOT) and ameloblastic fibroma; these cases should be evaluated thoroughly^[4,10].

In addition, Langlais^[9] refers that the lateral variant of the DC can be confused with the paradental cyst (PC) being its main differences the following: The PC is usually accompanied by a partially erupted third molar with pericoronitis and the lateral DC is associated with an unerupted tooth; the PC has a crescent or flame shape when small, while the lateral DC is more symmetrical and rounded; the PC rarely grows many centimeters while the lateral DC can occupy the entire hemimandibula; the scleral margin of the PC is thick or thickened, that of the lateral DC is thin and well defined.

The present study was conducted with the aim of evaluating the radiographic characteristics of dentigerous cysts (DC) diagnosed at the Faculty of Stomatology of the Universidad Peruana Cayetano Heredia (UPCH) during the Period of 2010–2017.

2. Material and methods

Descriptive, observational and cross-sectional study. The case selection procedure began with the

review of the database of anatomopathological diagnoses of the Buccomaxillofacial Pathology Laboratory between January 2010 and July 2017. After that, the database of digital radiographs of the Buccomaxillofacial Radiology Service of the UPCH was reviewed.

The sample population was selected by convenience and included all cases diagnosed in the period that met the inclusion criteria.

Thirty-seven digital panoramic radiographs were taken with the Sirona Orthophos XG 5, which operates from 60 Kv to 90 Kv and from 3 mA to 12 mA, and the digital images were exported to a compatible Lenovo H61 computer. Sidexis Next Generation software was used to generate the images.

The review of the radiographs was performed under the strict supervision of a specialist in Oral and Maxillofacial Radiology with more than 10 years of experience.

In each panoramic radiograph, the lesion was evaluated by observing the characteristics under study.

A form was used to record the following variables: age, sex, location, density, limits, borders, multilocularity, dental piece included in the lesion, involvement of adjacent anatomical structures and in 12 cases that presented other types of projections, the involvement of the bone tables was evaluated.

The methodology proposed for the research was reviewed and approved by the Institutional Ethics Committee of the UPCH. It should be emphasized that since the research was a retrospective review of radiographic records, no new patients were exposed to ionizing radiation for research purposes.

3. Results

The total number of diagnosed cases of dentigerous cysts was 233, which after inclusion and exclusion criteria, 37 cases were obtained.

The minimum age was 8 years and the maximum age was 75 years, with a mean age of 22.8

years. Dentigerous cyst was more frequent in women, with 19 cases (51.4%), while men accounted for 18 cases (48.6%).

The anatomical location of the lesions is described in **Table 1** and **Figure 1**.

The distribution of radiographic features of density, boundaries, borders and internal configuration are shown in **Table 2**, **Figure 2** and **Figure 3**.

It was observed that 37 cases (100%) of dentigerous cysts were associated with an unerupted tooth and the highest percentage corresponded to the third molars (51.3%), the distribution of the associated teeth is detailed in **Table 3** and **Figure 4**. In addition, in 17 cases (45.9%) the root apex was open, in 18 cases (48.6%) the apex was open and in two cases it was not possible to evaluate the apex. The involvement of adjacent teeth and lamina dura is detailed in **Table 4** and **Figure 5**.

The effects produced by the lesion to adjacent anatomical structures in cases of the lower jaw are shown in **Table 5** and **Figure 5**. Additionally, in the sample there were 12 cases (100%) that presented other types of radiographs such as posteroanterior, Towne's inverse or occlusal and it was possible to record the displacement of the bone tables, 7 cases (58.3%) presented displacement of the vestibular bone table, in 3 cases (25%) the bone tables were not affected, in 1 case (8.3%) the lingual table was affected and similarly in one case (8.3%) both bone tables were affected.

Table 1. Distribution according to location of dentigerous cysts in the jaws

Location	n	%
Superior		
Previous	3	8.1
Subsequent	1	2.7
Anterior and posterior	4	10.8
Posterior and tuberosity	7	18.9
Inferior		
Previous	1	2.7
Subsequent	12	32.4
Anterior and posterior	2	5.4
Posterior angle and branch	1	2.7
Rear and angle	1	2.7
Rear and branch	5	13.5
Total	37	100.0

Table 2. Distribution according to density, boundaries, edges and internal configuration

Radiographic Characteristics	n	%
Density		
Radiolucent	36	97.3
Mixed	1	2.7
Limits		
Defined	25	67.6
Partial definition	11	29.7
Not defined	1	2.7
Edges		
Corticalized	20	54.1
Partial corticization	11	29.7
Clipped	5	13.5
Transition	1	2.7
Internal configuration		
Unilocular	35	94.6
Multilocular	2	5.4
Total	37	100.0

Table 3. Distribution according to the associated dental piece

Associated dental	n	%
18	2	5.4
13	2	5.4
11	1	2.7
23	1	2.7
24	1	2.7
25	1	2.7
28	4	10.8
Senior supernumerary	3	8.1
38	7	18.9
37	1	2.7
35	2	5.4
43	2	5.4
45	1	2.7
46	1	2.7
47	2	5.4
48	6	16.2
Total	37	100.0

Table 4. Distribution according to involvement of teeth and supporting structure

Affection of teeth and supporting structure	n	%
Dental pieces		
Scroll	4	10.8
Reabsorbs	9	24.3
Displaces and reabsorbs	2	5.4
No affect	21	56.8
Not applicable	1	2.7
Hard foil		
Slim	3	8.1
Reabsorb	22	59.5
No affect	8	21.6
No registrable	4	10.8
Total	37	100.0

Table 5. Distribution according to involvement of bone structures of the lower jaw

Infection to bony structures of the lower jaw	n	%
Cortical cortex of the mandibular bi-axis		
Slim	4	18.2
Slimming and reabsorption	3	13.6
No affect	15	68.2
Lower dental canal		
Scroll	12	54.5
No affect	10	45.5
Total	22	100.0

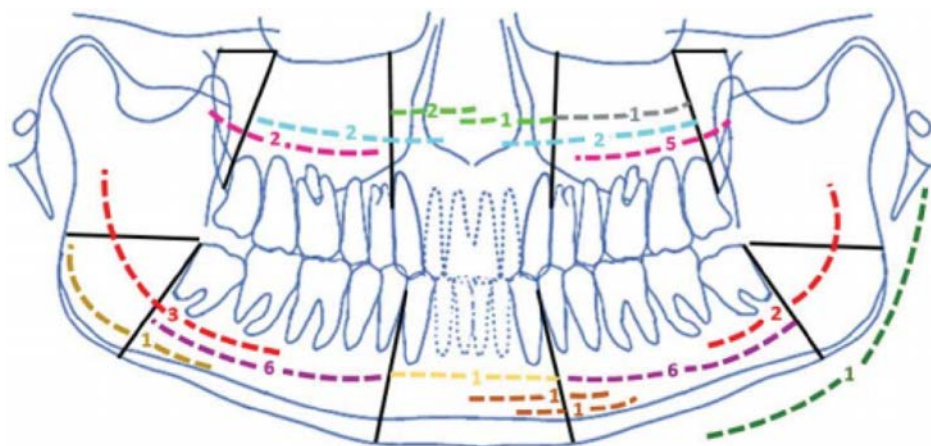


Figure 1. Location of dentigerous cysts in the jaws.

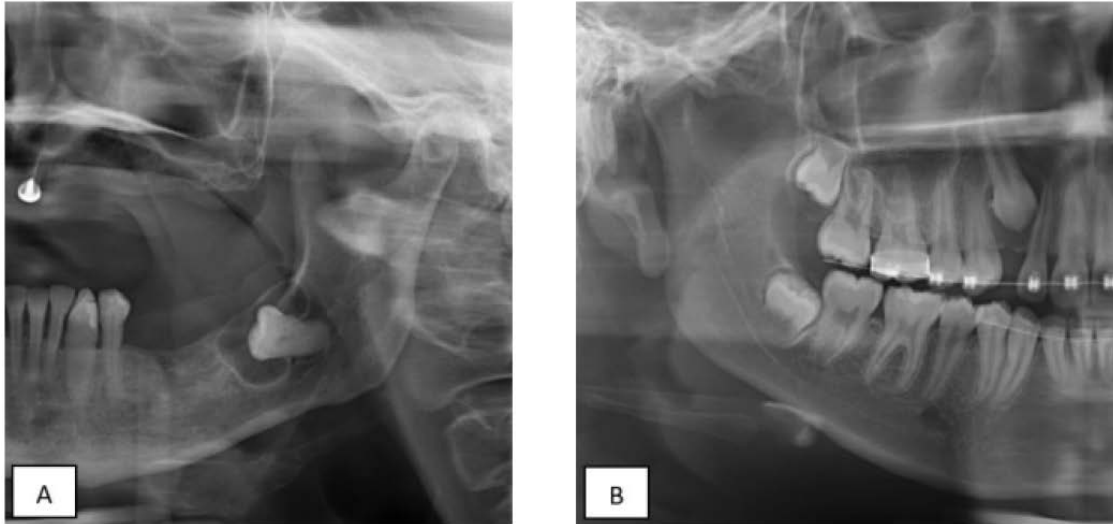


Figure 2. Density of the lesion: **A)** radiolucent image associated with specimen 38. **B)** mixed image associated with specimen 13.

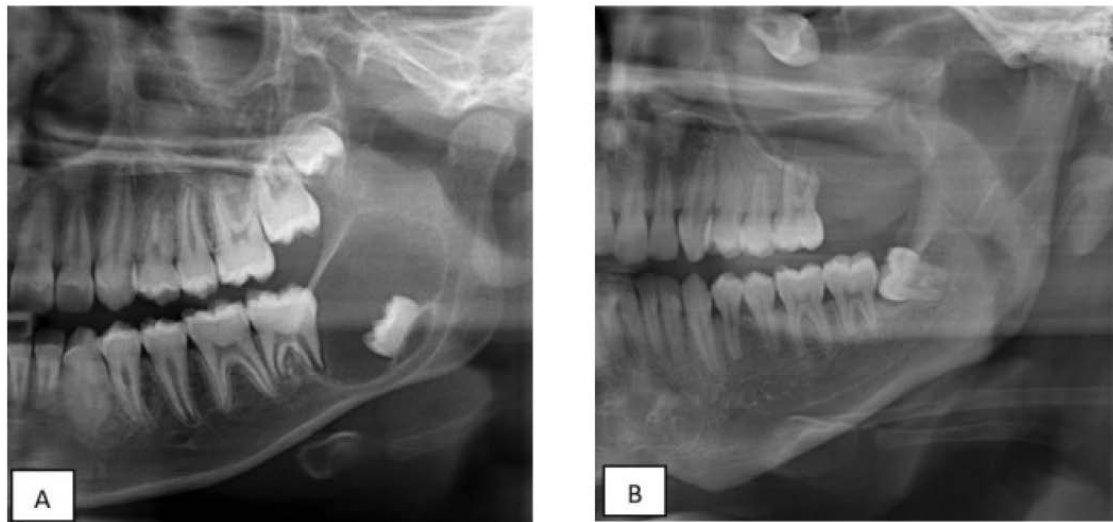


Figure 3. Limits and borders of the lesion: **A)** defined limits, corticated borders; **B)** partially defined boundaries and partially corticated edges.

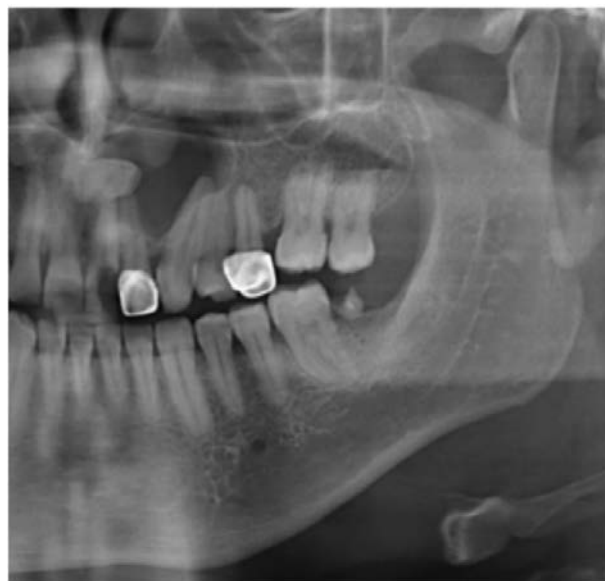

Figure 4. Dentigerous cyst associated with a supernumerary tooth.

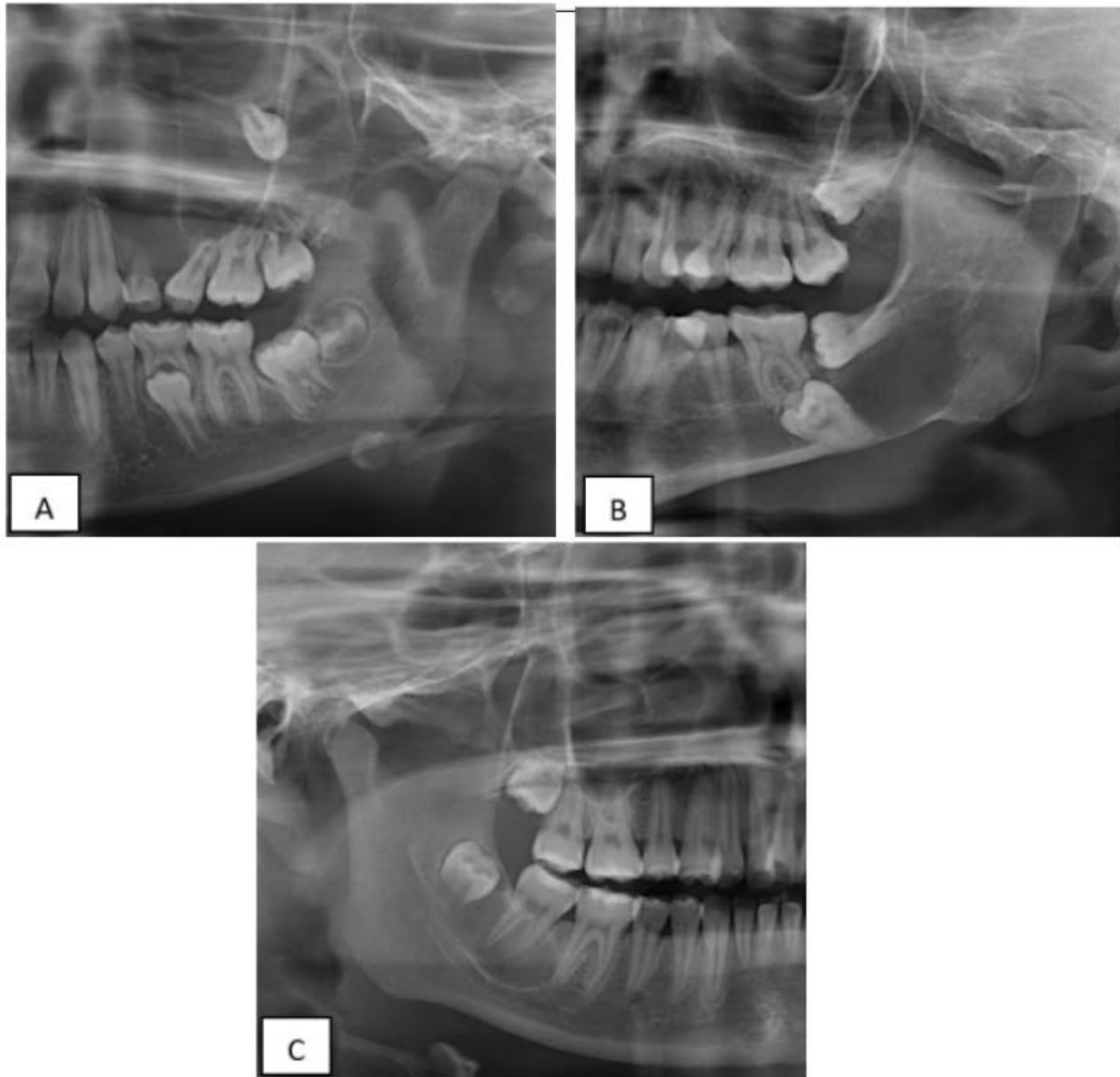


Figure 5. Affection to adjacent structures and dental pieces: **A)** Root displacement and resorption, **B)** Thinning of the mandibular basal, **C)** Caudal displacement of the inferior dental canal.

4. Discussion

In the present study it was found that the highest number of cases of dentigerous cysts were located in the second decade of life, similar to the data obtained by Sridevi *et al.*^[12] and Kambalimath *et al.*^[13], but different from the study by Demirkol *et al.* where the highest number of cases of dentigerous cysts were located in the third and fourth decade of life^[14]. However, the World Health Organization (WHO) cites that the incidence of this pathology occurs between the second and fourth decade of life^[15]. This data is important and leads to deduce that the cases diagnosed in the Buccomaxillofacial Pathology Laboratory of the Dental Clinic-UPCH occurred in young people, which has a favorable prognosis, reducing or avoiding cases of

over-aggregated infections or malignancies.

Regarding sex, most reports indicate a predilection for men, as is the case in countries and regions such as India^[13], Mexico^[16] and Taiwan^[17]. In this study we found a slight predilection for women (51.4%), which is due to the fact that a greater number of cases of men were eliminated because they did not meet the inclusion criteria.

Of all cases in this study, 59.9% were located in the mandible, this predilection for the lower jaw agrees with most of the literature^[14,15]. The most affected areas in the mandible were the posterior zone, followed by the posterior zone and ramus, which harbored 45.9% of the cases, this preference for the posterior zone agrees with the systematic review of 2082 dentigerous cysts by Zhang *et al.*^[18].

Table 6 shows the characteristics of the dentigerous cysts in terms of age, sex and most fre-

quent location, comparing the present study with other studies from different parts of the world.

Table 6. Cases of dentigerous cysts in different countries

Features	Number of cases	Average age (years)	Range (years)	Sex		Location	
				Male	Female	Maxilla	Jaw
Present study	37	28.1	1–80	18	19	15	22
Chile ^[19]	546	-	1–90	344	202	246	300
China ^[20]	281	11.8	1–18	187	94	160	118
*Mexico ^[21]	309	-	1–60	191	118	110	159
Portugal ^[22]	28	26	1–70	17	9	9	19

* 40 cases did not specify location

The vast majority of reports show that the dentigerous cyst is radially transparent (97.3%) however, there was a case where it showed a small calcification within the radiolucent universe, so it was considered mixed, which is unusual and there are few reports about it, such as Shibasaki *et al.*, who reported a case where the dentigerous cyst adopted a mixed aspect, the author mentions that this happened due to the infection of the cyst by actinomyces, which penetrated the lesion through the periodontal pocket of the associated tooth and absorbed calcium and other minerals from the crevicular fluid forming calcifications around the crown of the included tooth^[23]. This causality regarding mixed density may motivate future research.

Numerous case reports coincide in that these lesions present with defined limits and corticalized borders^[4,8]; but when these lesions present partially defined or not defined with partially corticalized borders, trimmed or in transition it is necessary to take into account possible infectious processes such as the one presented by López-Carriches *et al.*^[24], and also possible malignancies as presented by Yasuoka *et al.*^[25]; the first one evidenced a case of sinusitis caused by an infected dentigerous cyst, which is an important data to take into account due to the symptomatology presented (soft tissue inflammation, pain, rhinorrhea, among others). Imaging showed partially defined limits and partially corticated borders.

The second showed a case of squamous cell carcinoma originating from a dentigerous cyst, with partially defined limits and partially corticated borders, the most frequent age for these cases being between the sixth and eighth decade of life.

In the systematic review of Bodner *et al.*, showed 116 cases of primary intraosseous carcinoma during 1998, they mention that the prevalence of this tumor derived from a dentigerous cyst was 16% (19 cases)^[26], they do not mention the radiographic characteristics, however, the 2017 WHO classification refers that in advanced stages they are shown with poorly defined limits and non-corticalized borders but in early stages they show radiographic signs of benignity, that is, defined limits with corticalized borders.

Multilocularity of the dentigerous cysts was another radiographic characteristic evaluated in this investigation. The result obtained was similar to that found by Yoshiura *et al.* who found 2 cases of multilocular dentigerous cysts in a sample of 31 cases^[27]. Likewise, Scholl *et al.* mentioned that this radiographic appearance (lobulated or multilocular) is generally seen in large dentigerous cysts; since due to the unequal speed of expansion through areas of variable bone density their borders acquire undulating characteristics, being the resulting radiographic appearance comparable to a keratocyst or ameloblastoma^[28]. The above mentioned is confirmed by the two cases of this research that presented multilocular aspect since these lesions presented large size and an appearance similar to keratocyst or ameloblastoma. Although it is true that these lesions usually present with a unicystic appearance, however, when we are faced with an extensive, multilocular lesion associated with a dental piece, we should also consider the dentigerous cyst as a diagnostic possibility.

The association of teeth with dentigerous cysts was also evaluated in terms of the type of tooth,

root formation and displacement of the teeth. It was found that the dentigerous cyst has a marked predilection for the molar areas of the mandible (45.9%), with the third molars being the most affected, data similar to those reported in studies of populations in Asia^[29], America^[30] and Europe^[31].

In this investigation, slightly more than half of the pieces associated with the lesion presented complete root formation. No reports or information on this characteristic were found in the literature consulted, so it could not be contrasted with the literature.

Another characteristic evaluated was the effect that dentigerous cysts may have on structures such as adjacent teeth, the basal mandibular cortex, the lower dental canal, the floor of the maxillary sinus and the lamina dura.

The majority of adjacent teeth (56.8%) were not affected (root resorption or caudal/cephalic displacement) by the cystic lesion, but 24.3% were found to have root resorption, which is significantly less than the study by Struthers *et al.*, who observed that the dentigerous cyst showed a tendency to resorb roots (55%) and suggest that the capacity of the dentigerous cyst for root resorption may be the result of its origin in the dental follicle, which is associated with the resorption of primary tooth roots during normal tooth succession^[32].

As for the inferior dental canal, 12 cases (54.5%) of 22 cases (100%) registered to this effect; the dentigerous cyst made contact with the inferior dental canal producing its caudal displacement, an important fact to take into account since Liang *et al.* mention that patients with mandibular dentigerous cysts can present paresthesia of the inferior alveolar nerve produced by the high pressure generated by these cysts or by the chemical corrosion of the nervous tissues due to inflammatory factors of the cysts^[33].

Of the dentigerous cysts that affected the upper jaw, 7 cases (46.7%) were found to displace the floor of the maxillary sinus and 1 case (6.7%) resorbed this anatomical structure; no reviews have been found to know and contrast the prevalence of this characteristic.

Other radiographic features evaluated in the

present study were the involvement of the mandibular basal and lamina dura of adjacent teeth.

For the first, it was found that of all the dentigerous cysts present in the lower jaw (22 cases), 68.2% of cases did not damage the mandibular basal and for the second it was found that of the 37 cases of dentigerous cysts, 22 cases (59.5%) resorbed the lamina dura of adjacent teeth. However, from the results obtained in this investigation, we can hypothesize that dentigerous cysts do not tend to thin and/or resorb the basal cortex, but they do tend to resorb the cortex of the lamina dura. This information gap could motivate future research to accept or reject the aforementioned hypothesis and as for the cortical lamina dura, it would be interesting to evaluate it by means of another imaging technique due to the limitations of panoramic radiography for this purpose.

In the literature consulted no reviews were found that allow us to contrast results about the displacement of bone tables associated with dentigerous cysts, however, numerous case reports were found such as Choi *et al.*,^[34] Buyukkurt *et al.*,^[35] and Freitas *et al.*,^[36] where this feature is observed.

5. Conclusions

Most of the results obtained on the characteristics in the Peruvian population support previous studies reported in America, Europe and Asia. Radiographically, the dentigerous cyst showed characteristics that support its clearly benign behavior.

Conflict of interest

The authors declare no conflict of interest.

References

1. Yahara Y, Kubota Y, Yamashiro T, *et al.* Eruption prediction of mandibular premolars associated with dentigerous cyst. *Oral Surgery, Oral Pathology, Oral Radiology, and Endodontology* 2009; 108(1): 28–31.
2. Qian W, Ma Z, Xie Q, *et al.* Marsupialization facilitates eruption of dentigerous cyst-associated mandibular premolars in preadolescent patient. *Journal of Oral and Maxillofacial Surgery* 2013; 71(11): 1825–1832.
3. Shibata Y, Asaumi J, Yanagi Y, *et al.* Radiographic examination of dentigerous cysts in the transitional

- dentition. *Dentomaxillofacial Radiology* 2004; 33(1): 17–20.
4. Konouchi H, Asaumi J, Yanagi Y, *et al.* Diagnostic value of MR imaging for dentigerous cysts. *Oral Radiology* 2014; 30(1): 13–19.
 5. Devi P, Thimmarasa VB, Mehrotra V, *et al.* Multiple dentigerous cysts: A case report and review. *Journal of Maxillofacial and Oral Surgery* 2015; 14(1): 47–51.
 6. Hedge R, Khare S, Deyrukhkar V. Dentigerous cyst in a young child: Clinical insight and a case report. *Journal of Indian Society of Pedodontics and Preventive Dentistry* 2013; 31(1): 209–211.
 7. Zapała-Pośpiech A, Wszyńska-Pawełec G, Adamek D, *et al.* Malignant transformation in the course of a dentigerous cyst: A problem for a clinician and a pathologist. Considerations based on a case report. *Polish Journal of Pathology* 2013; 64(1): 64–68.
 8. Jeon JY, Park CJ, Cho SH, *et al.* Bilateral dentigerous cysts that involve all four dental quadrants: A case report and literature review. *Journal of the Korean Association of Oral and Maxillofacial Surgeons* 2016; 42(2): 123–126.
 9. Langlais RP, Langland OE, Nortje CJ. Generalised radiopacities: Osteopetrosis. In: Langlais RP, Langland OE, Nortje CJ (editors). *Diagnostic Imaging of the Jaws*. Malvern: Williams and Wilkins; 1995. p. 598–613.
 10. Albarrán G, Gutierrez R, Yépez Y. Marsupialización como tratamiento para quiste dentífero en un paciente pediátrico. Reporte de caso (Spanish) [Marsupials as a treatment for dental cysts in pediatric patients. Case report]. *Revista Odontológica de Los Andes* 2014; 9(1): 47–55.
 11. Kouhsoltani M, Mesgarzadeh A, Moradzadeh M. Mandibular fracture associated with a dentigerous cyst: Report of a case and literature review. *Journal of Dental Research, Dental Clinics, Dental Prospects* 2015; 9(3): 193–198.
 12. Sridevi K, Kaushik A, Ramaswamy P, *et al.* Dentigerous cysts of maxillofacial region-clinical, radiographic and biochemical analysis. *Kathmandu University Medical Journal* 2015; 13(1): 8–11.
 13. Kambalimath DH, Kambalimath HV, Agrawal SM, *et al.* Prevalence and distribution of odontogenic cyst in Indian population: A 10-year retrospective study. *Journal of Maxillofacial and Oral Surgery* 2014; 13(1): 10–15.
 14. Demirkol M, Ege B, Yanik S, *et al.* Clinicopathological study of jaw cysts in southeast region of Turkey. *European Journal of Dentistry* 2014; 8(1): 107–111.
 15. Speight P, Fantasia J, Neville B. *Odontogenic and non-odontogenic developmental cysts*. WHO Classification of Head and Neck Tumours. 4th ed. Lyon: WHO; 2017. p. 234.
 16. Mosqueda A, Irigoyen M, Díaz M, *et al.* Quistes odontogénicos. Análisis de 856 casos (Spanish) [Odontogenic cysts. Analysis of 856 cases]. *Medicina Oral*. 2002; 7(1): 89–96.
 17. Lin H, Wang Y, Chen H, *et al.* A clinicopathological study of 338 dentigerous cysts. *Journal of Oral Pathology & Medicine* 2013; 42(6): 462–467.
 18. Zhang L, Yang R, Li W. Dentigerous cyst: A retrospective clinicopathology analysis of 2082 dentigerous cysts British Columbia, Canada. *International journal of oral and maxillofacial surgery* 2010; 39(9): 878–882.
 19. Ochsenius G, Escobar E, Godoy L, *et al.* Odontogenic cysts: Analysis of 2944 cases in Chile. *Medicina Oral, Patología Oral y Cirugía Bucal* 2007; 21(1): 85–91.
 20. Li N, Gao X, Xu Z, *et al.* Prevalence of developmental odontogenic cysts in children and adolescents with emphasis on dentigerous cyst and odontogenic keratocyst (keratocyst odontogenic tumor). *Acta Odontologica Scandinavica* 2014; 72(8): 795–800.
 21. Villasis L, Portilla J, Melendez A, *et al.* Prevalence and distribution of odontogenic cysts in a Mexican sample: A 753 cases study. *Journal of clinical and experimental dentistry* 2017; 9(4): 531–538.
 22. Monteiro L, De la Peña J, Fonseca L, *et al.* Odontogenic cysts-A descriptive clinicopathological study. *Brazilian Journal of Oral Sciences* 2005; 4(12): 670–675.
 23. Shibasaki M, Iwai T, Chikuma H, *et al.* Actinomyces associated calcifications in a dentigerous cyst of the mandible. *Journal of Craniofacial Surgery* 2013; 24(3): 311–314.
 24. Lopez-Carriches C, Lopez-Carriches I, Bryan R. Odontogenic sinusitis caused by an inflammation of a dentigerous cyst and subsequent finding of a fibrous dysplasia: A case report. *The Open Dentistry Journal* 2016; 30(10): 647–655.
 25. Yasuoka T, Yonemoto K, Kato Y, *et al.* Squamous cell carcinoma arising in a dentigerous cyst. *Journal of oral and maxillofacial surgery* 2000; 58(8): 900–905.
 26. Bodner L, Manor E, Shear M, *et al.* Primary intraosseous squamous cell carcinoma arising in an odontogenic cyst: A clinicopathologic analysis of 116 reported cases. *Journal of oral pathology & medicine* 2011; 40(10): 733–738.
 27. Yoshiura K, Higuchi Y, Araki K, *et al.* Morphologic analysis of odontogenic cysts with computed tomography. *Oral Surgery, Oral Medicine, Oral Pathology, Oral Radiology, and Endodontology* 1997; 83(6): 712–718.
 28. Scholl R, Kellett H, Neumann D, *et al.* Cysts and cystic lesions of the mandible: Clinical and radiologic histopathologic review. *Radiographics* 1999; 19(5): 1107–1124.
 29. Yeo JF, Zain RB, Ti LS, *et al.* Clinicopathological study of dentigerous cysts in Singapore and Malaysia. *Malaysian Journal of Pathology* 2007; 29(1): 41–47.
 30. Avelar RL, Antunes AA, Carvalho RWF, *et al.* Odontogenic cysts: A clinicopathological study of

- 507 cases. *Journal of oral science* 2009; 51(4): 581–586.
31. Henien M, Sproat C, Kwok J, *et al.* Coronectomy and dentigerous cysts: A review of 68 patients. *Oral Surgery, Oral Medicine, Oral Pathology and Oral Radiology* 2017; 123(6): 670–674.
 32. Struthers P, Shear M. Root resorption by ameloblastomas and cysts of the jaws. *International Journal of oral surgery* 1976; 5(3): 128–132.
 33. Liang Y, He W, Zheng P, *et al.* Inferior alveolar nerve function recovers after decompression of large mandibular cystic lesions. *Oral diseases* 2015; 21(5): 674–678.
 34. Choi HJ, Lee JB. Obliteration of recurrent large dentigerous cyst using bilateral buccal fat pad sling flaps. *Journal of Craniofacial Surgery* 2016; 27(5): e465–e468.
 35. Buyukkurt MC, Omezli MM, Miloglu O. Dentigerous cyst associated with an ectopic tooth in the maxillary sinus: A report of 3 cases and review of the literature. *Oral Surgery, Oral Medicine, Oral Pathology, Oral Radiology, and Endodontology* 2010; 109(1): 67–71.
 36. Freitas DQ, Tempest LM, Sicoli E, *et al.* Bilateral dentigerous cysts: Review of the literature and report of an unusual case. *Dentomaxillofacial Radiology* 2006; 35(6): 464–468.