

ORIGINAL RESEARCH ARTICLE

Control chest x-ray in patients with asymptomatic posttraumatic pneumothorax

Julieta Correa-Restrepo^{1*}, Mónica Restrepo-Moreno¹, Luis Guillermo Peláez¹, Rafael Díaz-Cadavid¹, Yuliana López-Vasco¹, María Alejandra Rojas¹, David Alejandro Mejía-Toro^{1,2}, Carlos Hernando Morales-Uribe^{1,2}

^{1*} Universidad de Antioquia, Medellín, Colombia. E-mail: julicore2003@gmail.com

² Hospital Universitario San Vicente Fundación, Medellín, Colombia.

ABSTRACT

Introduction: Chest trauma has a high incidence and pneumothorax is the most frequent finding. The literature is scarce on what to do with asymptomatic patients with pneumothorax due to penetrating chest trauma. The aim of this study was to evaluate what are the findings of the control radiography of patients with penetrating chest trauma who are not initially taken to surgery, and their usefulness in determining the need for further treatment. **Methods:** A retrospective cohort study was performed, including patients older than 15 years who were admitted for penetrating chest trauma between January 2015 and December 2017 and who did not require initial surgical management. We analyzed the results of chest radiography, the time of its acquisition, and the behavior decided according to the findings in patients initially left under observation. **Results:** A total of 1,554 patients were included, whose average age was 30 years, 92.5% were male and 97% had a sharp weapon wound. Of these, 186 (51.5%) had no alterations in their initial X-ray, 142 had pneumothorax less than 30% and 33 had pneumothorax greater than 30%, hemopneumothorax or hemothorax. Closed thoracostomy was required as the final procedure in 78 cases, sternotomy or thoracotomy in 2 cases and discharged in 281. **Conclusion:** In asymptomatic patients with small or moderate pneumothorax and no other significant lesions, longer observation times, radiographs and closed thoracostomy may be unnecessary.

Keywords: Thoracic Trauma; Pneumothorax; Diagnosis; Imaging; Thoracic Radiography; Conservative Treatment

ARTICLE INFO

Received: 2 May 2021
Accepted: 20 June 2021
Available online: 30 June 2021

COPYRIGHT

Copyright © 2021 by author(s).
Imaging and Radiation Research is published by EnPress Publisher LLC. This work is licensed under the Creative Commons Attribution-NonCommercial 4.0 International License (CC BY-NC 4.0).
<https://creativecommons.org/licenses/by-nc/4.0/>

1. Introduction

Chest trauma occurs frequently throughout the world and is more common in developing countries; it accounts for 60% of polytrauma cases, with a morbidity and mortality of up to 25%^[1].

Traumatic pneumothorax is the most frequent finding and consists of air accumulation between the parietal and visceral pleura. Its diagnosis is made by postero-anterior chest radiography in upright position, and the sensitivity in supine position was low (79 Vs. 8%)^[2]. Pneumothorax is produced by a direct or indirect injury to the thorax, which generates a valve mechanism with a seal around the wound in the subcutaneous plane, allowing air to enter the pleural space. However, the pathophysiology of late pneumothorax or late findings changes, because they are due to thrombi and adhesions that disintegrate over time, allowing late air passage^[3,4]. The most frequent anatomical locations are anterior, basal and apical^[5].

The clinical presentation varies widely and it is in high demand emergency departments where asymptomatic patients become a distracting factor, generating the need for periods of observation and addi-

tional studies, since it is considered that 2% may develop pneumothorax late, for which control radiographs and serial physical examination are needed^[6]. The control X-ray is usually taken within six hours of the trauma, but in some studies, it has been shown that less follow-up time would be sufficient without significant risk^[7,8].

This study was developed in view of the scarce literature on the conduct to be followed in asymptomatic patients or with mild findings in the initial chest images, the lack of knowledge of the epidemiological data and the number of lesions diagnosed with control radiographs, in addition to the lack of information on the local incidence of intrathoracic lesions that may manifest late and their association with other complications.

Its purpose was to evaluate the findings of control radiography in patients with penetrating chest trauma who are not initially taken to surgery and its usefulness in determining the need for further management.

2. Methods

A retrospective cohort study was conducted with patients older than 15 years old at the Hospital Universitario San Vicente Fundación de Medellín from January 2015 to December 2017.

Inclusion criteria were diagnosis of penetrating chest trauma and not requiring initial surgical treatment. Patients with hemodynamic instability or who had undergone urgent surgery, who requested voluntary discharge and who had received extra-institutional care were excluded. For the search, the International Classification of Diseases, tenth edition (ICD-10) codes related to chest trauma were included.

The medical records were reviewed and demographic data on age and sex were taken, as well as clinical data such as type of wound and location, vital signs on admission, time between the trauma and the initial X-ray, X-ray findings and other studies requested, initial behavior, time between the initial and control X-ray, control X-ray findings and final behavior, as well as the need for readmission for the same cause and definitive diagnosis.

The main outcome evaluated was the

change between the initial and control radiographs, with the need for surgical intervention in patients initially left under observation.

The data collected were recorded in an ExcelTM database of Microsoft Office 2013. With StataTM software, version 22, a descriptive analysis of the variables, tables and graphs of the results obtained were made. For continuous variables, Abstract measures were used and, for qualitative variables, absolute and relative frequencies were used.

3. Results

A total of 3,543 medical records were analyzed. A total of 1,989 were excluded for the following reasons: 1,151 patients had blunt trauma, 141 patients signed a voluntary discharge before chest X-ray, 246 patients required emergent surgery without previous imaging, 212 patients were revisions, and 10 patients died on admission. The other causes of exclusion are listed in **Figure 1**. In the end, 1,554 patients were included.

The average age was 30 years, the median was 27 years, with a minimum of 15 years and a maximum of 93 years (interquartile range from 21 to 36 years). Of the affected patients, 92.5% were male. During the initial evaluation, the mean systolic blood pressure was 120 mm Hg and heart rate was 90 beats per minute, with a range from 79 to 103 (**Table 1**).

The most frequent location of the wound was in the posterior thorax (44.6%) followed by the anterior thorax (30.8%), and 13.8% of the patients had multiple wounds. In 97% of the patients, the causal object was a sharp weapon; in the remaining patients, the cause was a firearm projectile wound.

Half of the patients underwent a chest X-ray within the first hour after the trauma and one third between one and three hours later. In this first X-ray, 993 (63.9%) patients had no abnormal findings, 206 (13.3%) had a pneumothorax less than 30%. A pericardial ultrasound was required as an additional study in 27.3% of patients, mainly those with a previous injury, in order to rule out cardiac lesions requiring urgent surgical intervention; the rest did not require any additional diagnostic aid.

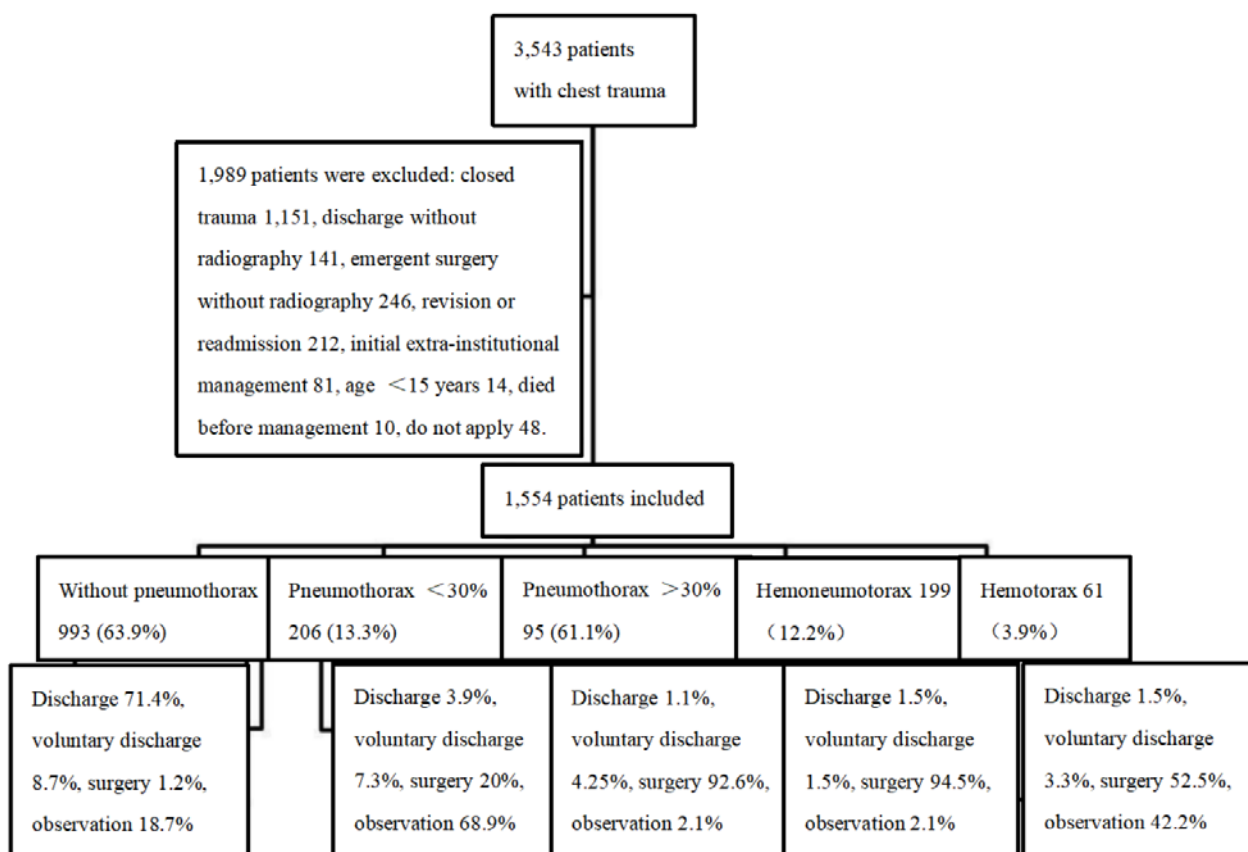


Figure 1. Patients included, exclusion criteria and initial radiographic findings.

Table 1. Demographic and clinical characteristics of the 1,554 patients included

Variable	n (%) or median (RIC)
Age	27 (21–36)
Male	1,437 (92.5)
Heart rate (beats per minute)	90 (79–103)
Systolic blood pressure (mm Hg)	120 (109–130)
Diastolic blood pressure (mm Hg)	76 (67–80)
Respiratory frequency	18 (17–20)
Wound location	
Chest, posterior	693 (44.6)
Chest, anterior	479 (30.8)
Left thoracoabdominal	79 (5.1)
Right thoracoabdominal	65 (4.2)
Zone I neck	24 (1.5)
Multiple wounds	214 (13.8)
Type of injury	
Sharp weapon	1,508 (97)
Firearm projectile	46 (3)

With the initial radiography, the need for thoracostomy was established in 22% of the cases, thoracotomy or sternotomy in 1.3%, and observation in 23.2%; in addition, discharge was decided in 46.5% (Table 2). Of the 993 patients with initial

radiography without hemothorax or pneumothorax, 709 (71.4%) were discharged without additional studies; 186 (18.7%) were left under observation and 86 (8.7%) were indicated for clinical observation and control radiography, but refused treatment

and voluntarily withdrew from the service.

A total of 361 patients were left under observation, 186 (79.6%) without pneumothorax, 142 (10.2%) with pneumothorax less than 30%, 2 (1.1%) with pneumothorax greater than 30%, 5 (5.4%) with hemopneumothorax and 26 (3.8%) with hemopneumothorax less than 300 mL. A control X-ray was taken in 9 (2.5%) patients during the first three hours after the trauma, in 202 (56%) between three and six hours, and in 150 (41.6%) after six hours.

Of the 186 patients with an initial radiography without any finding, 148 (79.6%) remained unchanged and 161 (86.6%) were discharged, while 19 (10.2%) presented a pneumothorax less than 30 % and 19 (10%) presented a pneumothorax

greater than 30 %, hemopneumothorax or hemothorax, requiring thoracostomy in 25 (13.4%) cases due to the finding in the control or for presenting symptoms (dyspnea, desaturation) (Tables 3 and 4).

In the two patients with pneumothorax greater than 30%, the finding in the control radiography persisted and they were taken to closed thoracostomy. Of the five patients with hemopneumothorax, one presented radiological improvement without intervention, one underwent thoracostomy and four were discharged. Of 26 patients with hemothorax left under observation, eight required thoracostomy, one required sternotomy, and 17 were discharged. Of these, pneumothorax was documented in 10, hemothorax in 6, empyema in 3, and intervention was needed in 7.

Table 2. Conduct taken with the admission chest X-ray

Conduct	Initial radiographic result					Total
	No pneumothorax: 993 (63.9%)	Pneumothorax <30%: 206 (13.3%)	Pneumothorax >30%: 95 (6.1%)	Hemopneumothorax: 199 (12.8%)	Hemothorax: 61 (3.9%)	
Thoracotomy	3 (0.3)	3 (1.5)	-	7 (3.5)	2 (3.3)	15 (1.0)
Closed thoracostomy	7 (0.7)	38 (18.5)	88 (92.6)	179 (90)	30 (49.2)	342 (22.0)
Sternotomy	2 (0.2)	-	-	2 (1)	-	4 (0.3)
Note	186 (18.7)	142 (68.9)	2 (2.1)	5 (2.5)	26 (42.2)	361 (23.2)
Discharge	709 (71.4)	8 (3.9)	1 (1.1)	3 (1.5)	1 (1.6)	722 (46.5)
Voluntary discharge	86 (8.7)	15 (7.3)	4 (4.25)	4 (1.5)	2 (3.3)	110 (7.1)

Table 3. Control radiography results in the group of patients under observation (n = 361)

Variable	No pneumothorax 186 (79.6%)	Pneumothorax <30% 142 (10.2%)	Pneumothorax >30% 2 (1.1%)	Hemopneumothorax 5 (5.4%)	Hemothorax 26 (3.8%)
No pneumothorax	148 (79.6)	22 (15.5)	-	-	6 (23.1)
Pneumothorax <30%	19 (10.2)	81 (57)	-	1 (20)	1 (3.9)
Pneumothorax >30%	2 (1.1)	15 (10.6)	2 (100%)	-	-
Hemopneumothorax	10 (5.4)	-	-	4 (80)	5 (19.2)
Hemothorax	7 (3.8)	24 (16.9)	-	-	14 (53.9)

Table 4. Behavior after control radiography in patients under observation

Variable	No pneumothorax 186 (79.6%)	Pneumothorax <30% 142 (10.2%)	Pneumothorax >30% 2 (1.1%)	Hemopneumothorax 5 (5.4%)	Hemothorax 26 (3.8%)
Thoracotomy	-	1 (0.7)	-	-	-
Closed thoracostomy	25 (13)	42 (29.6)	2 (100)	1 (20)	8 (30.8)
Sternotomy	-	-	-	-	1 (3.9)
High	161 (86.6)	99 (69.7)	-	4 (80)	17 (65.4)

4. Discussion

Traumatic pneumothorax is a common injury, both in blunt and penetrating chest trauma. It can become life-threatening, requiring urgent sur-

gical interventions, mainly in symptomatic patients with pleural findings, associated injuries or need for mechanical ventilation. However, in asymptomatic patients, treatment and observation time have been controversial.

There is no established method for determining the exact size of a pneumothorax on radiography. Different strategies have been used for this purpose, such as Light's index, Rhea's method and Collins' method. Light's index consists of measuring the diameter of the collapsed lung and the diameter of the hemithorax, assuming that the ratio between the cube of both measurements correlates with the volume of the pneumothorax^[9]. In Collins's method, as in Rhea's, three interpleural distances are measured, but are related to measurements taken with helical computed tomography (CT)^[10].

In addition to these three classic methods for measuring pneumothorax, there are guidelines that recommend other parameters for calculating the size of the pneumothorax. In 2001, the American College of Chest Physicians (ACCP) classified pneumothoraces as small or large according to the interpleural distance at the pulmonary apex: less than or greater than 3 cm, respectively^[11]. In 2003, the British Thoracic Society (BTS) classified them in the same way, but according to an interpleural distance at the level of the pulmonary hilum, equal to or less than 2 cm^[12]. To date, there is no international consensus on how to determine the size of the pneumothorax. In the population under study in this report, the Light index was used.

The incidence of occult pneumothorax varies between 1.8% and 26%, with an average of 5%, although up to 64% has been reported in severe polytrauma^[2,13,14]. Attempts have been made to identify risk factors predictive of occult pneumothorax in patients with chest trauma and severe trauma. A significant association with subcutaneous emphysema was found in 22% of cases. All patients with emphysema had an associated pneumothorax, open or occult, and these were not found to predict other conditions, such as rib fractures or pulmonary contusions^[3].

Attempts have been made to improve the diagnosis with additional studies in addition to chest radiography. CT and ultrasound have increased 3.5 times the thoracic findings of nonspecific or insignificant clinical significance, with a sensitivity of up to 98.1%. However, evidencing an occult pneumothorax has not generated significant changes in

the management of many of these cases, different from what could be a pneumothorax of up to 30% in asymptomatic patients^[13,15-17]. In this study, CT was used in only 2.3% of cases and subxiphoid ultrasound in 27.3%, to evaluate associated cardiac lesions, not in search of an occult pneumothorax.

Currently, there is no consensus on when to intervene for occult pneumothorax. For several years, Advanced Trauma Life Support (ATLS) has been recommending chest tubes to treat pneumothorax^[18]. However, conservative treatment for these patients has been an option that, although not fully recommended due to the high risk of developing a tension pneumothorax, has been practiced over time because the thoracostomy can be morbid and cause complications in up to 22-30% of cases^[19,20]. In several studies and case reports, it has been shown that conservative treatment can be effective and the complications of thoracostomy can be avoided^[1,21,22].

Several studies have found that, when the initial radiograph is negative or normal in cases of stab wounds, late pneumothorax is uncommon (2.2%) and thoracostomy is required in 1.1% of patients^[3,4]. Previous series on penetrating chest wounds reported late pneumothorax or hemothorax in 8 to 12% of cases, and recommended surveillance for up to 72 hours^[8,23], which would not be practical in our setting and, possibly, would not generate significant additional impact.

There is no consensus on when conservative treatment is indicated depending on the size of the pneumothorax. Some studies suggest that it may be effective and safe when the pneumothorax is 10-15% or less than 2.5 cm of the interpleural space on chest radiograph, and recommend observation for at least 24 hours^[24]. A pneumothorax resorption rate of approximately 1.25% per day has been calculated^[18,25-27]. However, there are reports of cases with pneumothorax of 30%, treated conservatively without complications and with complete resolution^[19]. Based on experience in this type of cases, at the Hospital San Vicente Fundación, asymptomatic patients with isolated pneumothorax of less than 30% receive conservative treatment.

The data suggest that conservative manage-

ment may be effective in patients without initial pneumothorax and with pneumothorax less than 30%. In this case, 71.4% of the patients without initial pneumothorax and 3.9% of those with pneumothorax less than 30% were discharged without a period of observation and without readmission; it should be taken into account that the former may include those with non-penetrating wounds. On the other hand, 18.9% of the patients without pneumothorax and 68.9% of those with pneumothorax less than 30% were left under observation; 13.4% of the former and 29.6% of the latter required closed thoracostomy as definitive treatment, either because of changes in the radiological findings, the appearance of symptoms or both.

During this study, more than half (68%) of the patients with pneumothorax less than 30% on the initial radiograph were left under observation and, in 73%, follow-up demonstrated improvement or no change from the previous radiograph. In 27% of the patients, the pneumothorax increased or was associated with hemothorax, and thoracotomy was required in one and closed thoracostomy in 42 (29.6%), which corresponded to 32% of the control radiographs between 3- and 6-hours post-trauma, and 25% of those taken after 6 hours.

In the present study, a control was taken 3 to 6 hours after the initial normal radiograph or with pneumothorax less than 30%, both findings considered as criteria for expectant management. In 22.2% of these cases (80/361), surgical treatment was required after the control X-ray. Most (56%) of the control studies were taken between the initial 3 and 6 hours; however, in 15.7% of the patients who had to undergo surgery, it was after 6 hours of admission, which can be explained by the heavy congestion of the hospital emergency department.

In a descriptive and prospective study it is stated that, out of 87 patients under observation, only one had to be operated on at 3 hours and, at 6 hours, there were no changes in the rest of the images and no further interventions were needed^[7]. Another study refers to the low incidence of late pneumothorax when the initial radiograph is normal, and the almost zero possibility of pneumothorax developing after 3 hours^[28].

Increasingly shorter radiographic follow-up intervals have been evaluated for injury exclusion and safe discharge. Weigelt *et al.* in a prospective study of asymptomatic patients with thoracic stab wounds found that 9% developed late hemothorax or pneumothorax^[6,29]. In selected patients, follow-up with a single radiograph three hours after the trauma is suggested, resulting in shorter hospital stays and less radiation exposure.

Other thoracic lesions, such as hemopneumothorax, require surgical treatment due to the risk of clotted hemopneumothorax, empyema or failure to resolve. In the present study, of the 199 patients who presented with hemopneumothorax, 188 underwent surgical procedures, with a total of 179 (90%) closed thoracostomies. In 20% of cases, pneumothorax may be associated with hemopneumothorax^[30]. However, asymptomatic patients, with a pneumothorax less than 30%, with occult pneumothorax or with hemothorax less than 300 mL, could be managed expectantly^[31].

In this study, we were unable to evaluate the economic cost of the observation period and the control radiography necessary to generate a potential change in medical behavior.

The main limitation of the present study is that, being retrospective, we do not have the follow-up of the 722 (46.5%) patients discharged after a single initial X-ray, who did not present readmissions or complications in this same institution. In the absence of a unified clinical history system and the lack of access to health care for this low-income population, it is not possible to ensure that they did not require any additional intervention in another institution. However, it can be considered that these patients, as well as those under observation whose radiography did not show any change, may not have needed it.

Taking into account that a significant percentage of patients who were left under observation eventually required closed thoracic surgery, we do not intend to change this behavior in the emergency department based on the present study. Prospective studies are needed to determine the possible results, the indicated observation time and the potential benefit of additional low-risk tests, such as

pleural ultrasound examinations.

5. Conclusion

Closed thoracostomy in patients with small or moderate traumatic pneumothorax, in the absence of other significant injuries or need for positive pressure, may be unnecessary, as may prolonged periods of observation and follow-up radiographs in patients with a normal initial radiograph or minimal findings. These patients could be safely discharged, thus decreasing hospital stay, irradiation and costs associated with observation.

Informed consent

This study is a retrospective review of clinical histories, considered a risk-free study according to Resolution 008430 of 1993 of the Colombian Ministry of Health; as such, it does not require informed consent. The Institutional Ethics Committee approved the study design and methodology.

Conflict of interest

The authors declare that they have no conflict of interest.

References

1. Mowery NT, Gunter OL, Collier BR, *et al.* Practice management guidelines for management of hemothorax and occult pneumothorax. *Journal of Trauma* 2011; 70: 510–518.
2. Ball CG, Dente CJ, Kirkpatrick AW, *et al.* Occult pneumothoraces in patients with penetrating trauma: does mechanism matter? *Canadian Journal of Surgery* 2010; 53: 251–255.
3. Ball CG, Ranson K, Dente CJ, *et al.* Clinical predictors of occult pneumothoraces in severely injured blunt polytrauma patients: a prospective observational study. *Injury* 2009; 40: 44–47.
4. Zehtabchi S, Morley EJ, Sajed D, *et al.* Delayed pneumothorax after stab wound to thorax and upper abdomen: truth or myth? *Injury* 2009; 40: 40–43.
5. Ball CG, Kirkpatrick AW, Laupland KB, *et al.* Factors related to the failure of radiographic recognition of occult posttraumatic pneumothoraces. *American Journal of Surgery* 2005; 189: 541–546.
6. Berg RJ, Inaba K, Recinos G, *et al.* Prospective evaluation of early follow-up chest radiography after penetrating thoracic injury. *World Journal of Surgery* 2013; 37: 1286–1290.
7. Shatz DV, de la Pedraja J, Erbella J, *et al.* Efficacy of follow-up evaluation in penetrating thoracic injuries: 3- vs. 6-hour radiographs of the chest. *The Journal of Emergency Medicine* 2001; 20: 281–284.
8. Kerr TM, Sood R, Buckman RF, *et al.* Prospective trial of the six-hour rule in stab wounds of the chest. *Surgery, Gynecology & Obstetrics* 1989; 169: 223–225.
9. Rhea JT, DeLuca SA, Greene RE. Determining the size of pneumothorax in the upright patient. *Radiology* 1982; 144: 733–736.
10. Collins CD, Lopez A, Mathie A, *et al.* Quantification of pneumothorax size on chest radiographs using interpleural distances: regression analysis based on volume measurements from helical CT. *AJR. American Journal of Roentgenology* 1995; 165: 1127–1130.
11. Baumann MH, Strange C, Heffner JE, *et al.* Management of spontaneous pneumothorax: An American College of Chest Physicians Delphi consensus statement. *Chest* 2001; 119: 590–602.
12. MacDuff A, Arnold A, Harvey J, *et al.* Management of spontaneous pneumothorax: British Thoracic Society Pleural Disease Guideline 2010. *Thorax* 2010; 65(Suppl.2): ii18–ii31.
13. Ball CG, Kirkpatrick AW, Feliciano DV. The occult pneumothorax: What have we learned? *Canadian Journal of Surgery* 2009; 52: E173–179.
14. Charbit J, Millet I, Maury C, *et al.* Prevalence of large and occult pneumothoraces in patients with severe blunt trauma upon hospital admission: experience of 526 cases in a French level 1 trauma center. *The American Journal of Emergency Medicine* 2015; 33: 796–801.
15. Mollberg NM, Wise SR, De Hoyos AL, *et al.* Chest computed tomography for penetrating thoracic trauma after normal screening chest roentgenogram. *The Annals of Thoracic Surgery* 2012; 93: 1830–1835.
16. Kea B, Gamarallage R, Vairamuthu H, *et al.* What is the clinical significance of chest CT when the chest X-ray result is normal in patients with blunt trauma? *The American Journal of Emergency Medicine* 2013; 31: 1268–1273.
17. Blaivas M, Lyon M, Duggal S. A prospective comparison of supine chest radiography and bedside ultrasound for the diagnosis of traumatic pneumothorax. *Academic Emergency Medicine* 2005; 12: 844–849.
18. Johnson G. Traumatic pneumothorax: Is a chest drain always necessary? *Emergency Medicine Journal* 1996; 13: 173–174.
19. Llaquet Bayo H, Montmany Vioque S, Rebaso P, *et al.* Results of conservative treatment in patients with occult pneumothorax. *Cirugía Española* 2016; 94: 232–236.
20. Tapias L, Tapias-Vargas LF, Tapias-Vargas L. Complications of chest tubes. *Revista Colombiana de Cirugía* 2009; 24: 46–55.
21. Idris BM, Hefny AF. Large pneumothorax in blunt chest trauma: Is a chest drain always necessary in stable patients? A case report. *International Journal*

- of Surgery Case Reports 2016; 24: 88–90.
22. Kirkpatrick AW, Stephens MV, Fabian T. Canadian Association of General Surgeons and American College of Surgeons evidence based reviews in surgery: Treatment of occult pneumothorax from blunt trauma. *Canadian Journal of Surgery* 2006; 49: 358–361.
 23. McLatchie GR, Campbell C, Hutchison JS. Pneumothorax of late onset after chest stabbings. *Injury* 1980; 11: 331–335.
 24. Molnar TF. Thoracic trauma: Which chest tube when and where? *Thoracic Surgery Clinics* 2017; 27: 13–23.
 25. Kircher LT, Swartzel RL. Spontaneous pneumothorax and its treatment. *Journal of the American Medical Association* 1954; 155: 24–29.
 26. Symington L, McGugan E. Towards evidence based emergency medicine: Best BETs from the Manchester Royal Infirmary. Bet 1: Is a chest drain necessary in stable patients with traumatic pneumothorax? *Emergency Medicine Journal* 2008; 25: 439–440.
 27. Henry M, Arnold T, Harvey J, *et al.* BTS guidelines for the management of spontaneous pneumothorax. *Thorax* 2003; 58(Suppl.2): ii39–ii52.
 28. Seamon MJ, Medina CR, Pieri PG, *et al.* Follow-up after asymptomatic penetrating thoracic injury: 3 hours is enough. *Journal of Trauma and Acute Care Surgery* 2008; 65: 549–553.
 29. Weigelt JA, Aurbakken CM, Meier DE, *et al.* Management of asymptomatic patients following stab wounds to the chest. *The Journal of Trauma* 1982; 22: 291–294.
 30. Mabry R, McManus JG. Prehospital advances in the management of severe penetrating trauma. *Critical Care Medicine* 2008; 36(Suppl.): S258–S266.
 31. Neff MA, Monk JS, Peters K, *et al.* Detection of occult pneumothoraces on abdominal computed tomographic scans in trauma patients. *Journal of Trauma and Acute Care Surgery* 2000; 49: 281–285.