

ORIGINAL RESEARCH ARTICLE

The prevalence and characterization of implant-related findings in panoramic radiographs

Silvia Barrientos Sánchez*, Adriana Rodríguez Ciodaro, David Martínez Laverde, Alejandro Curan Cantoral

Pontificia Universidad Javeriana, Bogotá, Colombia. E-mail: barrien@javeriana.edu.co

ABSTRACT

Introduction: In Colombia, the last oral health study showed that about 70% of the population has partial edentulism while 5.2% will have lost all their teeth between the age of 65 and 79. Rehabilitation with implants is an increasingly used option, which requires clinical and radiographic follow-up. Panoramic radiography is a low-cost option, in which it is possible to observe areas of bone loss, mesiodistal angulation of the implant, relationship with anatomical structures and lesions suggestive of peri-implantitis. Reports and analysis of relevant data on radiographic findings associated with dental implants are required to determine the risk factors for their success in patients who use them. **Objective:** To determine the prevalence and characterize the findings associated with osseointegration implants in panoramic radiographs. **Methods:** A descriptive cross-sectional observational study was carried out with 10,000 digital panoramic radiographs selected by convenience from radiological centers in the city of Bogota, Colombia, of which 543 corresponded to the sample analyzed for the presence of implants. The following were evaluated for each implant: location, position, angulation and distances to adjacent structures, using the ClínicaView® program (Orthopantomograph OP200D, Instrumentarium, USA). **Results:** The frequency of radiographs with implants was 5.43% with a total of 1,791 implants, with an average of 3.2 per radiograph. They were found in greater proportion in the upper jaw with a supracrestal location and an angulation of 10.3 degrees. 32% had implant/tooth or implant/implant distances that were less than optimal. 40.9% were restored and 1.2% showed lesions compatible with periimplantitis. **Conclusions:** A high percentage of the implants reviewed have a risk factor that affects their long-term viability, either due to angulation, supracrestal or crestal position, proximity to teeth or other implants, or because they are not restorable.

Keywords: Radiographic Findings; Panoramic Radiographs; Dental Implants

ARTICLE INFO

Received: 2 March 2021
Accepted: 11 April 2021
Available online: 28 April 2021

COPYRIGHT

Copyright © 2021 by author(s).
Imaging and Radiation Research is published by EnPress Publisher LLC. This work is licensed under the Creative Commons Attribution-NonCommercial 4.0 International License (CC BY-NC 4.0).
<https://creativecommons.org/licenses/by-nc/4.0/>

1. Introduction

Tooth loss is a relevant problem that not only affects esthetics and mastication, but is also related to alterations in tooth position, bone resorption, tooth extrusion, periodontal diseases and phonation, among others^[1]. According to the National Oral Health Study (ENSAB IV)^[2], in Colombia, 45% of the patients attend dentistry consult for tooth loss. Classifying them by age, in the 15 to 19 age group, 3.9% of the teeth were absent or indicated for extraction, age 35 to 44, the loss of teeth increased to 8 teeth per person and in those over 55 the loss was 16.2 teeth per individual. In this same study, it was determined that the prevalence of edentulism in Colombia is 25% in both jaws and 7% in the lower jaw only.

The clinical approach to the partially or totally edentulous patient has had several approaches with the use of fixed, removable and total prostheses in which their success depends on the position, availability or absence of dental abutments. In this sense, implant dentistry is emerging

as an option that can provide a wide variety of abutment locations depending on the quantity and quality of bone present in the patient. The success of implant placement and rehabilitation is based on the diagnosis and correlation of clinical and imaging findings, including computed tomography and panoramic radiographs, for treatment planning and follow-up of conventional implants^[3]. The evaluation before and after implant placement includes the evaluation of the anatomical structures, detection of diseases, estimation of the quantity and quality of the bone, trajectories of insertion of the implants with respect to the angulation of the alveolar ridge and proximity to natural teeth or other conventional dental implants in the mouth; these same items should be evaluated in the immediate postoperative period^[4].

The follow-up after implant placement is done through clinical examination looking for mobility, inflammation, infection and radiographic control with panoramic images that due to their sensitivity and specificity, although limited, allow suspicion of associated bone lesions^[5], and has been useful in long-term studies as it shows data on peri-implantitis, relationships of implants with adjacent teeth or implants and proximity to neighboring structures such as the maxillary sinuses or mandibular canal^[6,7]. Restoration with implants should be evaluated to identify and quantify the associated risk factors and their impact on oral morbidity profiles, especially when it is a technology that is being accessed more frequently every day. The objective was to determine the prevalence and characterize the findings associated with osseointegration implants in panoramic radiographs.

2. Methods

A descriptive observational study was carried out with the approval of the Research and Ethics Committee of the Faculty of Dentistry of the Pontificia Universidad Javeriana. A universe of 10,000 digital panoramic radiographs from radiological centers in the city of Bogota was selected by convenience sampling, of which 543 corresponded to the sample analyzed for the presence of implants. Digital radiographs of persons over 18 years of age were included, with adequate density, sharpness, contrast or focus,

without evidence of vertical and horizontal distortion, or artifacts such as prosthesis not removed or other damage that did not allow the correct visualization of the complete image.

The observations were carried out by two of the researchers, specialists in Maxillofacial Surgery trained in osseointegration, using the computers of the Dental Clinics of the Faculty. Once the radiographs were selected according to the inclusion criteria, for the measurements a systematic and ordered reading of each digital panoramic radiograph was made, which was divided into four zones: superior right, superior left, inferior left and inferior right, using the ClinicView® 9.3 program (Orthopantomograph OP200D, Instrumentarium, USA). This program allows measurements to be taken directly on the image, from the previously defined points, as shown in **Figure 1**. The measurements taken were the following: distances between the evaluated implant and the adjacent tooth or implant and its angulation with respect to a line parallel to the bone midline, drawn through the anterior nasal spine and chin points (**Figure 1**).

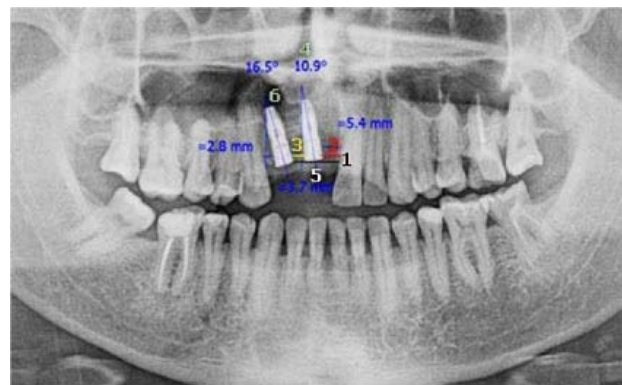


Figure 1. Description of the measurements taken for the characterization of the implants in the panoramic radiographs. Note: 1: location according to alveolar bone crest; 2: distance to contiguous tooth; 3: distance to contiguous implant; 4: angulation with respect to midline; 5: presence or absence of prosthetic crown; 6: presence or absence of peri-implant lesion.

The results were tabulated in an Excel spreadsheet, in which general data on age and sex were included. In addition to recording the number of implants, the following characteristics were studied: type of implant (conventional, juxtaosseous or zygomatic), location (maxillary or mandibular anterior defined as the area between the central and lateral

teeth, middle, between canines and premolars and posterior molars), angulation, presence of peri-implant lesion (bone loss greater than 2 mm around the implant, distance of the implants with contiguous teeth and implants, presence of rehabilitation and total edentulism in upper or lower jaw or both. The chi-square test was used for comparisons between groups and the odds ratio was calculated in cases where a relationship between variables was sought. $p < 0.05$ was accepted as the significance value.

3. Results

In the 10,000 radiographs analyzed, the patients presented an average age of 38.4 (SD: ± 15.4), with a variation between a minimum age of 18 and a maximum age of 92, for 42.4% of the male sex. The prevalence of dental implants in the studied population, reported when a radiograph presented at least one implant, was found to be 5.43% (1,791 implants in total), with an average of 3.2 implants per radiograph. Of the 543 radiographs with implants, 45% were male and 55% female, with an average age of 52 years. No statistically significant difference was found between the two sexes.

Implant characterization was performed for the variables studied in the 1,791 implants found. According to the type of implant, 98.9% were endosseous, including zygomatic implants (18 implants) and 1.1% were juxtaosseous. The 18 zygomatic implants were found in 5 patients without pathologic findings. Eight patients had 12 juxtaosseous implants with variation between 1 and 3 per individual, some with signs of bone loss.

According to the location, at maxillary level, 57.62% (1,032) of the implants were found mostly (419 implants) in the premolar area. In the mandible the number decreased to 42.38% (759), preferentially placed in the posterior area. The anatomical location of the implants is summarized in **Table 1**.

The analysis of implant angulation showed an average of 10.3 degrees with a standard deviation of ± 8.95 degrees in anteriors, ± 10.48 degrees in premolars and ± 10.88 degrees in the posterior segment. Of the conventional implants, 2.06% (37) presented angulations greater than 30 degrees; of the anterior implants, 59.5% were in supracrestal position and 40.5%

in crestal position; 15 of these implants were rehabilitated and 2 presented some type of peri-implant lesion. When calculating the odds ratio, the implants in which there are mesiodistal angulations greater than 30 degrees was found, the risk of having a lesion compatible with peri-implantitis is increased by 4.7 times.

Table 1. Location of the implants according to the anatomical zones

Anatomical area	n	%
Anterior maxilla	406	22.7
Middle jaw	419	23.4
Posterior maxilla	207	11.6
Anterior mandibular	152	8.5
Middle mandibular	238	13.2
Posterior mandibular	369	20.6

The frequency of radiographic findings compatible with peri-implant lesions was 1.22% with respect to the total number of implants, with no difference between sexes, but an evident increase with the patient's age.

Table 2 summarizes the situation of the implants with respect to bone, adjacent teeth and implants. The analysis of these risk factors indicates that, with respect to interdental distance, 14.9% of all implants had a distance of less than 1.5 mm with adjacent teeth and 21.7% had a distance of less than 3 mm with adjacent implants. Four of the implants that showed radiographic findings compatible with peri-implant lesion presented a distance of less than 1.5 mm between implant-tooth. The odds ratio calculation showed that there were 2.3 times more radiographic findings compatible with peri-implant lesions in sites where the ideal distances were not maintained.

Regarding rehabilitation, of the 40.9% (734) rehabilitated implants, 51.6% were in a supracrestal location, 42.7% crestal and 5.7% infracrestal. When observing the restored implants, it was found that 89% (655) presented an occlusal pair that makes it functional. There were 96 fixed prostheses in the 543 radiographs and of these 23 corresponded to dental implant-supported prostheses, while 73 were implant-supported prostheses, although the preponderance were the individually rehabilitated implants.

Other findings showed that 4.2% of the images with implants corresponded to upper and lower total edentulous individuals and that they used between 1

and 13 with an average of 5.4 implants per patient. Of the total edentulous individuals in the upper jaw, 4.9% used an average of 4.7 implants per patient

ranging from 1 to 12, while for the total edentulous patients in the lower jaw, 2.9% of the individuals used an average of 4.9 implants ranging from 1 to 11.

Table 2. Relationship of the position of the implants with respect to the neighboring structures

Position	n	%
Supracrestal	918	51.3
Crestal	733	40.9
Infracrestal	140	7.8
Total	1,791	100
Distance interdental		
Distance <1.5 mm with distal contiguous tooth	112	6.3
Distance >1.5 mm to distal neighbouring teeth	482	26.9
Distance <1.5 mm with mesial adjacent tooth	156	8.7
Distance >1.5 mm with mesial adjacent tooth	611	34.1
No adjacent tooth	430	24
Total	1,791	100
Plantar in-rim distance		
Distance <3.0 mm with distal contiguous implant	153	8.5
Distance >3.0 mm with distal abutting implant	478	26.7
Distance <3.0 mm with mesial contiguous implant	237	13.2
Distance >3.0 mm with mesial adjacent implant	689	38.5
No adjacent implant	234	13.1
Total	1,791	100

4. Discussion

The National Oral Health Study^[2] reports that only 0.17% of Colombians have dental implants, which is explained by economic limitations and the existence of other prosthetic solutions that are faster and more affordable to solve the esthetic and functional problem of edentulism. In our sample, the frequency of implants increases to 5.43% with respect to the general Colombian population because it analyzes individuals in urban areas with access to better dental services.

These epidemiological data are important because they serve as a basis for evaluating the behavior of implants and their impact on oral health, by analyzing the risk factors that may be associated with implant loss. Radiographic variables were observed, such as location, mesodistal angulation, bone relations and peri-implant lesions, relevant variables in the prognosis for implant survival^[8], since their anchorage and the adequate distribution of masticatory forces depend on them^[9].

The location of implants in the anterosuperior area suggests that the patient's need to initially rehabilitate the esthetic sector is more important, despite the fact that the loss of posterior teeth in both the upper and lower jaw is greater^[2]. It is known that the rehabilitation of the posterior sector is a priority for

the stability of occlusion and the prevention of joint damage, although the results of the present study show that sometimes these implants do not have antagonists, which leaves them without function.

The evidence proposes to angulate the implants looking for the maximum bone stability and viability of a prosthesis in the long term and, in general, accepts ranges between 30 and 35 degrees; the reports support great predictability and preservation for the implants and the prostheses supported on them^[10]. For zygomatic implants, the average angulations can be from 35 to 45.7 degrees, having great stability and longevity^[11]. When presenting greater angulation, excessive tension is produced in the interface bone crest-platform of the implant, loss that becomes progressive if the tension is not relieved^[12]. In this study, because it was performed in two-dimensional images, it was only possible to see the mesodistal angulation of the implants, which in general terms, is within the ranges accepted by the evidence to support masticatory loads. It should be noted that the implants that presented greater angulations also had greater crestal and supracrestal bone loss and in fact a greater probability of peri-implant lesions^[13].

Regarding the distances between teeth and implants, in order to maintain the integrity of the papilla and achieve optimal esthetic results, it should not be less than 3 mm between two implants, and between

tooth-implant it should not be less than 1.5 mm^[8]. However, animal studies have shown that the proximity between implants and teeth can induce resorption and pulp necrosis, and in fact these are the cause of malpractice claims in clinical practice^[14,15].

In the sample of the present study, 85.1% of the implants present a distance greater than or equal to 1.5 mm with adjacent teeth and 78.3% have a relation greater than or equal to 3 mm between contiguous implants; the above suggests that most implants present a good prognosis for this factor, especially in anterior teeth, with regard to the esthetic result between the definitive rehabilitation of the implant and the formation of an adequate papilla. Despite the fact that 21.7% of the implant-implant measurements present a lower ratio than indicated in the literature, there is controversy regarding crestal bone resorption over time, among implants placed at a distance equal to or less than 1.8 mm^[16]. Bearing in mind that the implant-bone interface and the height of the alveolar bone in relation to the dental implant platform also influence the crestal or supracrestal location of an implant and could decrease the longevity of the implant in the long term^[17–20].

Additionally, the loss of crestal bone, the exposure of the platform and the threads of the implant are a risk factor for the development of peri-implantitis, which are associated with plaque accumulation on the implant surface^[21,22]. However, within the limitations of the tool used in this study, no conclusions can be drawn on clinical aspects, nor can these findings be correlated with the clinic.

Another aspect shown in this study is that the rehabilitation rate of these implants is only 40.9% (734), probably because the prosthesis implies an important cost, or also because an implant may be correctly osseointegrated but not necessarily rehabilitable due to its position or angulation, taking into account that one of the restrictions of the panoramic image is the analysis of the implant in the vestibulo-lingual direction.

Radiographic findings compatible with peri-implant lesions in the apical area of the implant were 1.2%, which is in agreement with other clinical studies where the prevalence of peri-implantitis is of the order of 1.7%. These can be caused during implant

placement, due to bone overheating during the drilling procedure and its proximity to the apices of the adjacent teeth causing a lesion^[23–25]. It is also evident that radiographic findings compatible with peri-implantitis increase with age, which confirms the findings of other authors^[13].

Taking into account the limitations of being a radiographic study, it can be concluded that a large number of the implants analyzed present risk factors for their loss, such as angulation values higher than those reported in the literature as correct for the restoration, placement errors in extreme proximity to teeth or implants and age.

Conflict of interest

The authors declare that there is no conflict of interest in the development of this research project.

References

1. Russel SL, Gordon S, Lukacs JR, *et al.* Sex/gender differences in tooth loss and edentulism: Historical perspectives, biological factors, and sociologic reasons. *Dental Clinics of North America* 2013; 57(2): 317–337.
2. Ministry of Health. IV Estudio Nacional de Salud Bucal (ENSAB IV) (Spanish) [IV national oral health study (ENSAB IV)]. Bogota: Colombian Ministry of Health; 2013.
3. Chugh NK, Bhattacharyya J, Das S, *et al.* Use of digital panoramic radiology in presurgical implant treatment planning to accurately assess bone density. *Journal of Prosthetic Dentistry* 2016; 116(2): 200–205. doi: 10.1016/j.prosdent.2016.01.017.
4. Gutmacher Z, Machtei EE, Hirsh I, *et al.* A comparative study on the use of digital panoramic and peri-apical radiographs to assess proximal bone height around dental implants. *Quintessence International* 2016; 47(5): 441–446. doi: 10.3290/j.qi.a35704.
5. Cortes AR, Eimar H, Barbosa J de S, *et al.* Sensitivity and specificity of radiographic methods for predicting insertion torque of dental implants. *Journal of Periodontology* 2015; 86(5): 646–655. doi: 10.1902/jop.2015.140584.
6. Machtei EE, Oettinger-Barak O, Horwitz J. Axial relationship between dental implants and teeth/implants: A radiographic study. *Journal of Oral Implantology* 2014; 40(4): 425–431. doi: 10.1563/AAID-JOI-D-12-00052.
7. Saulacic N, Abboud M, Pohl Y, *et al.* Implant-supported mandibular overdentures and cortical bone formation: Clinical and radiographic results. *Implant Dentistry* 2014; 23(1): 85–91. doi: 10.1097/ID.0000000000000000032.
8. Caubet J, Heras I, Sanchez J, *et al.* Management of

- anteroposterior bone defects in aesthetic restoration of the front teeth. *Revista Española de Cirugía Oral y Maxilofacial* 2009; 31(2): 81–97.
9. Aradya A, Kumar UK, Chowdhary R. Influence of different abutment diameter of implants on the peri-implant stress in the crestal bone: A three-dimensional finite element analysis—In vitro study. *Indian Journal of Dental Research* 2016; 27(1): 78–85. doi: 10.4103/0970-9290.179836.
 10. Behnaz E, Ramin M, Abbasi S, *et al.* The effect of implant angulation and splinting on stress distribution in implant body and supporting bone: A finite element analysis. *European Journal of Dentistry* 2015; 9(3): 311–318. doi: 10.4103/1305-7456.163235.
 11. Ishak MI, Abdul Kadir MR, Sulaiman E, *et al.* Finite element analysis of different surgical approaches in various occlusal loading locations for zygomatic implant placement for the treatment of atrophic maxillae. *International Journal of Oral and Maxillofacial Surgery* 2012; 41(9): 1077–1089. doi: 10.1016/j.ijom.2012.04.010.
 12. Guzmán S. Criterios de éxito y fracaso en implantes dentales oseointegrados (Spanish) [Criteria for success and failure in osseointegrated dental implants]. *Acta Odontológica Venezolana* 2013; 51(2): 150–158.
 13. Negri M, Galli C, Smerieri A, *et al.* The effect of age, gender, and insertion site on marginal bone loss around endosseous implants: Results from a 3-year trial with premium implant system. *BioMed Research International* 2014; 2014: 369051. doi: 10.1155/2014/369051.
 14. Pinchi V, Varvara G, Pradella F, *et al.* Analysis of professional malpractice claims in implant dentistry in Italy from insurance company technical reports, 2006 to 2010. *International Journal of Oral and Maxillofacial Implants* 2014; 29(5): 1177–1184.
 15. Lee YK, Kim JW, Baek SH, *et al.* Root and bone response to the proximity of a mini-implant under orthodontic loading. *Angle Orthodontist* 2010; 80(3): 452–458.
 16. Danza M, Zollino I, Avantaggiato A, *et al.* Distance between implants has a potential impact of crestal bone resorption. *Saudi Dental Journal* 2011; 23(3): 129–133.
 17. Jo DW, Yi YJ, Kwon MJ, *et al.* Correlation between interimplant distance and crestal bone loss in internal connection implants with platform switching. *International Journal of Oral and Maxillofacial Implants* 2014; 29(2): 296–302.
 18. Siadat H, Panjnoosh M, Alikhasi M, *et al.* Does implant staging choice affect crestal bone loss? *Journal of Oral and Maxillofacial Surgery* 2012; 70(2): 307–313.
 19. Misch CE, Perel ML, Wang HL, *et al.* Implant success, survival, and failure: The International Congress of Oral Implantologists (ICOI) Pisa Consensus Conference. *Implant Dentistry* 2008; 17(1): 5–15.
 20. Al Amri MD. Influence of interimplant distance on the crestal bone height around dental implants: A systematic review and meta-analysis. *Journal of Prosthetic Dentistry* 2016; 115(3): 278–282.
 21. Duque AD, Aristizabal AG, Londoño S, *et al.* Prevalence of peri-implant disease on platform switching implants: A cross-sectional pilot study. *Brazilian Oral Research* 2016; 30. doi: 10.1590/1807-3107BOR-2016.vol30.0005.
 22. van Eekeren P, Tahmaseb A, Wismeijer D. Crestal bone changes in macrogeometrically similar implants with the implant-abutment connection at the crestal bone level or 2.5 mm above: A prospective randomized clinical trial. *Clinical Oral Implants Research* 2015; 21. doi: 10.1111/clr.12581.
 23. Trullenque-Eriksson A, Guisado Moya B. Retrospective long-term evaluation of dental implants in totally and partially edentulous patients: Part II: Peri-implant disease. *Implant Dentistry* 2015; 24(2): 217–221.
 24. De Bruyn H, Vandeweghe S, Ruyffelaert C, *et al.* Radiographic evaluation of modern oral implants with emphasis on crestal bone level and relevance to peri-implant health. *Periodontology* 2000 2013; 62(1): 256–270.
 25. Pabst AM, Walter C, Ehbauer S, *et al.* Analysis of implant-failure predictors in the posterior maxilla: A retrospective study of 1395 implants. *Journal of Cranio-Maxillofacial Surgery* 2015; 43(3): 414–420.